



International Journal of Orthopaedics Sciences

ISSN: 2395-1958
IJOS 2018; 4(1): 527-530
© 2018 IJOS
www.orthopaper.com
Received: 26-11-2017
Accepted: 27-12-2017

Prabhakar Rajamanickam
Associate Professor, Department
of Orthopaedics, Government
Medical College, Thoothukudi,
Tamil Nadu, India

Kannan Pillappan
Assistant Professor, Institute of
Orthopaedics and Traumatology,
Rajiv Gandhi Government
General Hospital, Chennai,
Tamil Nadu, India

Dr. Sathish Muthu
Post Graduate student, Institute
of Orthopaedics and
Traumatology, Rajiv Gandhi
Government General Hospital,
Chennai, Tamil Nadu, India

Santhosh Balaji
Post Graduate student,
Government Railway Hospital,
Perambur, Chennai, Tamil Nadu,
India

Facet joint malorientation as a cause of disc degeneration and prolapse in cases with backache: A radiological analysis

**Prabhakar Rajamanickam, Kannan Pillappan, Dr. Sathish Muthu and
Santhosh Balaji**

DOI: <https://doi.org/10.22271/ortho.2018.v4.i1h.76>

Abstract

Background: Facet tropism is defined as asymmetry between the left and right vertebral facet-joint angles, with one joint having a more sagittal orientation than the other. The goals of the present investigation were to examine the association between facet tropism and disc degeneration as well as disc herniation to determine the relationship between increased sagittal orientation of the facet joint. It is postulated that non-coherent movements of facets on either side leads to an altered biomechanical stress which has to be borne by the anterior structure that is the disc this leading to disc degeneration and earlier prolapse.

Methods: Axial and sagittal sections of MRI of the L4 L5 levels of 49 symptomatic adults aged between 20 to 60 years has been taken and their disc degeneration was classified from the T1 and T2 weighted MRI scans and facet tropism was graded as Mild (6-10 degrees), Moderate (11-15 degrees), Severe (>15 degrees).

Results: It was observed from our study that the greater the grades of disc degeneration was found in patients with higher degrees of mal-orientation. There is a 5.893 times risk of disc degeneration in the cases of malorientation of the facet joint. There was no significant difference between the male and female population with regard to facet tropism as a risk factor for disc degeneration.

Conclusion: In our present study the association between the facet tropism as a risk factor for degeneration is positively established. The alteration in the biomechanical forces in the cases of facet tropism thus has led to faster disc degeneration.

Keywords: Facet tropism, disc degeneration, facet malorientation

Introduction

Facet tropism is defined as asymmetry between the left and right vertebral (apophyseal) facet joint angle, with one joint having a more sagittal orientation than the other. For years, it has been postulated that this could result in inter-vertebral disc degeneration and herniation. The results of several studies concerning the association between the facet tropism and disc degeneration had been conflicting each other [1, 2, 3]. With magnetic resonance imaging, it is possible to obtain data on tropism of facet joints and measure facet joint angles and disc degeneration at the corresponding level can be obtained in symptomatic volunteers without the risk of ionising radiation and also reducing the cost of the study [4, 5]. The goals of the present study were to examine the association between facet tropism and disc degeneration as well as disc herniation and to determine the relationship between increased sagittal orientation of the facet joint at the level of L4-L5 with the help of the axial and sagittal sections of MRI of the L4 L5 levels.

Materials and Methods

This was a retrospective study carried out in the Institute of Orthopaedics and Traumatology, Rajiv Gandhi General Hospital, Chennai, Tamil Nadu from January 2016 to June 2016 for a period of 6 months. Axial and sagittal sections of MRI of the L4 L5 levels of the 49 symptomatic adults with chronic back ache aged between 20 – 60 years were included in the study and patients with MRI lacking clearer cuts at the level of measurement of the facet angle

Correspondence
Prabhakar Rajamanickam
Associate Professor, Department
of Orthopaedics, Government
Medical College, Thoothukudi,
Tamil Nadu, India

were excluded from the study. The sections are taken in such a way that the end plates are perpendicular to the long axis of the spine and scans were not used if the angle of the axial slice deviated by more than 5 degrees from the end plate which is evaluated from the CT console before enrolling the patient into study. Axial cuts were used to make out the facet angle and sagittal sections were used to determine the grade of the disc degeneration at the L4 L5 levels.

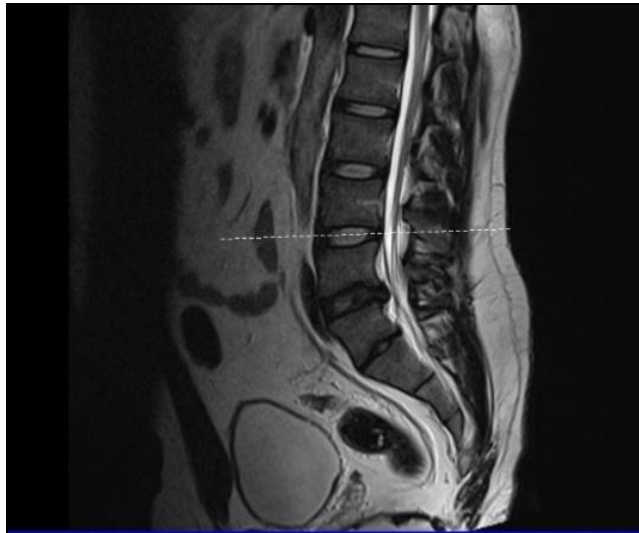


Fig 1: MRI picture: Sagittal section of spine to confirm perpendicularity of plate

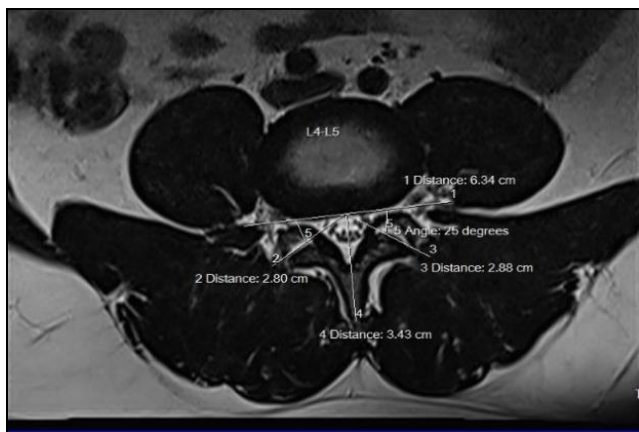


Fig 2: MRI picture: Coronal section where the facet angle is measured

Measurement of the Facet Angle

An axial magnetic resonance scan was made aligned parallel to the end plate at the level of the facet joint for the interspace between L4 and L5. The operator defined the sagittal reference plane by marking two points, one on the mid-point

of the posterior border of the vertebrae and one at the posterior most point of the spinous process. The line joining the two gave the sagittal plane. A line was drawn on the posterior border of the vertebral body. A line passing through the facet joint was drawn on the posterior border of the vertebral body. A line passing through the facet joint was drawn on each side intersecting line joining the points on the posterior border of the body of vertebra gave the facet joint orientation angle. The difference between the angle for the right facet and the angle for the left facet at each level (tropism) were then calculated. Facet tropism of more than 6 degrees was considered significant. All facet angles were measured independently by two observers who were blinded with regard to the diagnosis, and a mean value was calculated for each facet angle. After all measurements had been calculated, the data were grouped and statistical analysis was performed.

Validation of the Measurement technique

To validate the measurement technique on magnetic resonance scans, angle of same facet joints were measured independently by the same two observers and the Pearson correlation coefficient was calculated. To estimate intra-observer error, the measurement on the facets was repeated by both of the observers 2 days later. To examine inter-observer error, all of the 100 measurements were made into duplicate by each observer and compared with use of Pearson correlation.

Classification of Disc degeneration

Disc degeneration was classified from the T1 and T2 weighted sagittal magnetic resonance scans as described by Horton and Daftari. We used this schema to assign a point value to the different grades of annular and nuclear degeneration. The annulus was graded as flat (0 points), bulging (1 point), or torn (2 points), and the nucleus were graded as white (0 points), speckled (1 point), or dark (2 points). Each scan was scored independently by two observers and the mean score were calculated. The mean scores for the annulus and nucleus were then added together to provide a score for over-all disc degeneration. The total possible disc degeneration score, therefore, ranged from 0 to 2 points.

Results

A total of 49 cases were chosen and analysis was made. Seven of the cases were excluded as the axial cuts were more than 5 degree to the end plate. The number of male and female cases was 20 and 22 respectively.

The mean age of the patients was 43.4 (range between 32 to 56).The mean degeneration grade observed from the study was 1.32.

Table 1: Sex vs Disc Degeneration

Sex		Disc Degeneration		Total
		0	1	
Female	Count % with Disc Degeneration	7	15	22
		41.2%	60.0%	52.4%
Male	Count % with Disc Degeneration	10	10	20
		58.8%	40.0%	47.6%
Total	Count % with Disc Degeneration	17	25	42
		100.0%	100.0%	100.0%

Facet tropism was graded as mild (6-10 degrees), Moderate (11-15 degrees), Severe (>15 degrees). It was observed that greater grades of disc degeneration was found in patients with severe degrees of mal-orientation (mean disc degeneration grade of 2.3 in moderate facet tropism 11-15 degrees and a

grade of 3.3 in individuals with severe facet tropism more than 15 degrees) there was no significant difference between the male and female population based on the gender in respect to facet tropism as risk factor for disc degeneration.

Table 2: Facet Tropism vs. Disc Degeneration

Facet Tropism		Disc Degeneration		Total
		0	1	
0	Count % with Disc Degeneration	15	14	29
		88.2%	56.0%	69.0%
1	Count % with Disc Degeneration	2	11	13
		11.8%	44.0%	31.0%
Total	Count % with Disc Degeneration	17	25	42
		100.0%	100.0%	100.0%

Using bivariate and multivariate analysis, it is observed that there is no difference in facet tropism based on sex. There is a 5.893 times risk of disc degeneration in cases with facet tropism.

Out of the 42 cases, disc degeneration was found in 25 cases. There was a clustering of the cases in the older age group (40-60 years) – 15 cases. In such cases 14 of them had associated with facet joint mal orientation (facet tropism of more than 10 degrees). In the 17 cases without disc degeneration, facet joint mal-orientation was found in only 2 (two) individuals. The mean facet tropism in this group was 5.3 degrees.

There is a 5.893 times risk of disc degeneration in cases with facet tropism, thus confirming the postulation of the study.

Discussion

The level L4 –L5 is chosen in the study as it is the commonest level where disc prolapse occurs as it is the most mobile segment and increased amount of stress the disc experiences. It is postulated that non-coherent movements of facets on either side leads to an altered biomechanical stress which has to be borne by the anterior structure that is the disc thus leading to disc degeneration and prolapse [6, 7].

The primary source of error was in the identification of the reference plane and the margins of the facet joint, which is operator dependent.

In 1980, Cyron and Hutton [8] postulated that tropism could lead to instability, with the joints rotating toward the side of the most oblique facet. A relationship between asymmetry of the lumbar facets and disc abnormality was suggested by Farfan *et al.* [9] and by others. Van Schaik *et al.* used computed tomography to measure tropism in 100 patients who had low-back pain or sciatica or both and found a relationship between facet tropism and disc herniation at the level of the fourth and fifth lumbar vertebrae.

Noren *et al.* studied fifty-four patients who had back pain and reported an association between disc degeneration (including herniation) and facet tropism at all lumbar levels. They used magnetic resonance scans to determine disc degeneration and computed tomography to measure facet tropism.

In a skeletal study by Youssef Maher *et al.* [10] in 2007 on the orientation of the lumbar facets as a cause for spondylolysis on 115 males with isthmic spondylolysis concluded that the individuals with more sagittal oriented facets in the lower lumbar vertebra incorporated with facet tropism are at a greater risk for developing isthmic spondylolysis at L5.

Another study in 2009 by Leonid Kalichman *et al.* [11] on Facet Orientation and Tropism and its association with facet joint osteoarthritis and degenerative spondylolisthesis on 191 subjects concluded that significant association between

sagittal orientation and OA of the lumbar facet joints and spondylolisthesis.

Gao *et al.* [12] showed in their study in 2012 on 156 patients that facet joint tropism was significantly greater in these patients compared with control subjects.

In one of the largest studies in asia-pacific region by Samartzis *et al.* [13] in 2016, assessing facet joint orientation in patients with spondylolisthesis, it was concluded that greater sagittal facet joint angulation was associated with L4-L5 spondylolisthesis.

In contrast, other studies have suggested that facet tropism has no clinical relevance. In 1981, Adams and Hutton performed a biomechanical analysis and concluded that axial torsion was not important in the development of disc degeneration. Hagg and Wallner did not find any association between tropism and herniated discs in forty-seven patients who had herniated discs, although they noticed increased asymmetry at the level of the fourth and fifth lumbar vertebrae in these patients.

Most individuals have some degree of facet asymmetry, but the definition of excessive asymmetry or tropism is somewhat arbitrary. The absolute orientation of the facet joints has been less well studied than tropism. In the present investigation, we found that more sagittally oriented facet joints at the level of the fourth and fifth lumbar vertebrae were highly associated with herniated discs.

Conclusion

In our present study the association between the facet tropism as a risk factor for degeneration is positively established. Cases were chosen ruling out other common etiologies for disc degeneration. The alteration in the biomechanical forces in cases of facet tropism thus leads to faster degeneration. MRI is used as a standalone investigation because both disc degeneration and facet orientation can be assessed in the same.

Funding Source – Nil

Conflict of Interest - Nil

Reference

1. Scott D, Boden MD *et al.* Orientation of the Lumbar Facet Joints: Association with Degenerative Disc Disease: J Bone Joint Surg Am. 1996; 78(3):403-11.
2. Adams MA, Hutton WC. The relevance of torsion to the mechanical derangement of the lumbar spine. Spine. 1981; 6:241-248.
3. Ahmed AM, Duncan NA, Burke DL. The effect of facet geometry on the axial torque-rotation response of lumbar

- motion segments. *Spine*. 1990; 15:391-401.
4. Badgley CE. The articular facets in relation to low back pain and sciatic radiation. *J Bone and Joint Surg*. 1941; 23:481-496.
 5. Boden SD, Davis DO, Dina TS, Patronas NJ, Wiesel SW. Abnormal magnetic resonance scans of the lumbar spine in asymptomatic subjects. A prospective investigation. *J Bone and Joint Surg*. 1990; 72-A:403-408.
 6. Brailsford JF. Deformities of the lumbosacral region of the spine. *British J. Surg*. 1928; 16:562-627.
 7. Cassidy JD, Loback D, Yong-Hing K, Tchang S. Lumbar facet joint asymmetry. Intervertebral disc herniation. *Spine*. 1992; 17:570-574.
 8. Cyron BM, Hutton WC. Articular tropism and stability of the lumbar spine. *Spine*. 1980; 5:168-172.
 9. Farfan HF, Huberdeau RM, Dubow HI. Lumbar intervertebral disc degeneration. The influence of geometrical features on the pattern of disc degeneration - a post mortem study. *J Bone and Joint Surg*. 1972, 54-56.
 10. Masharawi YM, Alperovitch-Najenson D, Steinberg N, Dar G, Peleg S, Rothschild B *et al*. Lumbar Facet Orientation in Spondylolysis: A Skeletal Study. *Spine* [Internet]. 2007; 32(6). Available from: http://journals.lww.com/spinejournal/Fulltext/2007/03150/Lumbar_Facet_Orientation_in_Spondylolysis__A.22.aspx
 11. Kalichman L, Suri P, Guermazi A, Li L, Hunter DJ. Facet orientation and tropism: associations with facet joint osteoarthritis and degenerative spondylolisthesis. *Spine*. 2009; 15;34(16):E579-85.
 12. Gao F, Hou D, Zhao B, *et al*. The pedicle-facet angle and tropism in the sagittal plane in degenerative spondylolisthesis: a computed tomography study using multiplanar deformations techniques. *J Spinal Disord Tech*. 2012; 25(2):E18-E22.
 13. Samartzis D, Cheung JPY, Rajasekaran S, Kawaguchi Y, Acharya S, Kawakami M *et al*. Critical Values of Facet Joint Angulation and Tropism in the Development of Lumbar Asia Pacific Research Collaboration Consortium. *Glob Spine J*. Degenerative Spondylolisthesis: An International, Large-Scale Multicenter Study by the AO Spine. 2016; 6(5):414-21.