



Original Research Article

USG guided platelet rich plasma therapy for chronic resistant tendinopathies – Is it the next gold standard?

TP Saravanakumar^{1,*}, Sathish Muthu²

¹Dept. of Orthopaedics, Govt. Medical College Hospital, Karur, Tamil Nadu, India

²Govt. Hospital, Velayuthampalayam, Karur, Tamil Nadu, India



ARTICLE INFO

Article history:

Received 28-11-2020

Accepted 15-12-2020

Available online 15-01-2021

Keywords:

Ultrasound

Platelet rich plasma

Tendinopathy

Tennis elbow

Platelet

ABSTRACT

Background: One of the most common and under-treated problems faced by orthopedic surgeons is tendinopathy. Contradictory to the initial belief that tendinopathies are an inflammatory pathology, the histopathological analysis suggested that it is a disease of degeneration with characteristic hypercellularity, vascular hyperplasia, and collagen disorganization. Platelet-rich plasma (PRP) is a treatment modality attempting to modulate chronic inflammation and stimulate tissue regeneration.

Materials and Methods: This is a prospective study conducted on patients having tendinopathies on an outpatient basis. PRP infiltration was done at the tendinopathy site for 95 patients between the ages of 18 to 65 years. The patients with tendinopathies resistant to conservative management were included. Pre-injection Disabilities of the Arm, Shoulder, and Hand (DASH) scores and Visual Analogue Score (VAS) were recorded. The patients were then injected with PRP at the site of the tendinopathy under ultrasound guidance and post-injection DASH and VAS scores were recorded.

Results: We had a total of 95 cases included in the study. The gender-wise distribution showed a male predominance with M:F ratio of 2:1. The age-wise analysis showed a predominant number of cases in the age group of 36-45 years (n=41). The mean pre-intervention DASH score and VAS score of the included patients were 56.32 (SD=12.4) and 7.5 (SD=1.4) respectively which significantly reduced to 26.67 (SD=9.6) and 3.1 (SD=0.9) respectively at 6 months follow-up (p<0.001). No complications were noted due to the procedure.

Conclusion: PRP injections are a safe and effective treatment for patients presenting with tendinopathies irrespective of their etiologies and location. All the included patients had a consistent improvement in their clinical symptoms with just a single dose thereby reducing the adverse effects due to chronic use of non-steroidal anti-inflammatory drugs and also minimize the risk of surgeries.

© This is an open access article distributed under the terms of the Creative Commons Attribution License (<https://creativecommons.org/licenses/by/4.0/>) which permits unrestricted use, distribution, and reproduction in any medium, provided the original author and source are credited.

1. Introduction

Due to the benefits and the minimal risks associated with PRP, it has become an attractive alternative in the management of tendinopathies when other conservative methods have failed.^{1,2} When the whole blood sample of the patient is subjected to centrifugation and platelet separation process, a supra-normal concentration of the platelet than the original whole blood sample results, which is called platelet-rich plasma (PRP).³ The PRP once injected into the

site of interest, initiates the release of growth factors and stimulates tissue regeneration.⁴

Basic fibroblast growth factor (bFGF) and Platelet-derived growth factor (PDGF) from the degranulation of the activated platelets have the highest mitogenic activity according to chromatographic analysis. Pleiotropic effects of FGF depends on other factors present at the site of action. There is an increasing consensus that structural proteins in the extracellular matrix may have growth factor-like activity thereby regulating cell activity. Endogenously released growth factors including insulin-like growth factor-1, tissue

* Corresponding author.

E-mail address: drsaro78@gmail.com (T. P. Saravanakumar).

growth factor- β , PDGF, bFGF, vascular endothelial growth factor participate in cell proliferation, tissue remodeling, and inflammatory regulation.⁵ PRP would provide an additional source of the aforesaid growth factors which along with the local intrinsic factors at the site of action generate an accentuated healing and regeneration.

Multiple variables of PRP such as clinical profile, dose, delivery vehicle, release kinetics have to be considered to attain the full benefit of the injection. PRP when used appropriately, is a revolution in the treatment of tendinopathies with just a milliliter of the patient's platelets.

The main aim of the study is to analyze the clinical efficacy of the management of chronic tendinopathies with the ultrasound-guided injection of the PRP. The study was also undertaken to analyze the age and sex distribution among various tendinopathies.

2. Materials and Methods

This is a prospective study conducted in clinically diagnosed tendinopathies who have failed conservative management for 6 weeks. Patients in the age group between 18-65 years were included in the study. The tendinopathy was diagnosed and characterized using ultrasonography (USG). Patients with thrombocytopenia with a platelet count of $<10^5$ /ul, septicemia, local infections, consistent use of nonsteroidal anti-inflammatory drugs within 48 hours of the procedure, or corticosteroid injection at the site of treatment or the use of systemic corticosteroids within a month were excluded from the study.

The PRP was infiltrated by a single physician using an aseptic technique using ultrasonography. We used a dual-spin leucocyte-rich variant of the platelet-rich plasma for all patients irrespective of the region involved. The patients were diagnosed to have tendinopathies clinically and pre-injection Disabilities of the Arm, Shoulder, and Hand (DASH) scores and Visual Analogue Score (VAS) were recorded. The patient was then injected with PRP at the site of the tendinopathy under ultrasound guidance and post-injection DASH and VAS scores were recorded. Patients were serially followed up.

We used IBM SPSS Ver 25 for statistical analysis. Mean and standard deviations (SD) were used for the presentation of continuous variables and proportions were used for nominal variables. A paired student t-test was used for comparison of the functional outcome measures pre-and post-intervention and a p-value less than 0.05 was considered statistically significant.

3. Results

We had a total of 95 cases included in the evaluation. The gender-wise distribution showed a male predominance with M:F ratio of 2:1. The age-wise analysis showed a predominant number of cases in the age group of 36-45

years(n=41), and with 32.6% cases between 26-35 years, 13.6% cases between 46-55 years, 7.3% cases between 18-25 years, and the rest 5.2% in the age group of 56-65 years as shown in Table 1.

Based on the diagnosis, 48.4% cases were of supraspinatus tendinopathy, 23% cases were of lateral epicondylitis, 14% were of De Quervain's tenosynovitis, 7% were of trigger finger, and 5% of medial epicondylitis. Of the total 46 cases of supraspinatus tendinopathy, 22 patients belonged to the age group of 26-35 years, 8 cases belonged to the age group of 36-45 years, 6 cases each belonged to the age group 18-25 years, and 46-55 years, 4 cases belonged to 56-65 years.

Fifteen cases of lateral epicondylitis belonged to the 36-45 year age group, 5 cases from 26-35 years, and 3 cases from 46-55 years with a total of 23 cases of lateral epicondylitis. A total of 14 Patients with De Quervain's tenosynovitis were included out of which 8 patients belonged to the age group of 36-45 years, 3 cases belonged to 46-55 years, rest occurred below 35 years. Predominant of cases of De Quervain's tenosynovitis were females.

A total number of 5 patients were included with Medial epicondylitis and 3 cases were from the 36-45 age group the rest above 46 years of age. Trigger finger was again common in the 36-45 years age group with 5 of the 7 patients falling in the 36-45 year age category. The mean pre-intervention DASH score and VAS score of the included patients were 56.32 (SD=12.4) and 7.5 (SD=1.4) respectively which significantly reduced to 26.67 (SD=9.6) and 3.1 (SD=0.9) respectively at 6 months follow-up ($p<0.001$) as shown in Figures 1 and 2. No complications were noted due to the procedure.

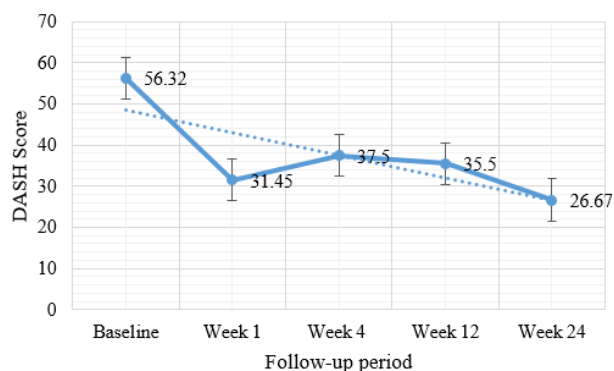


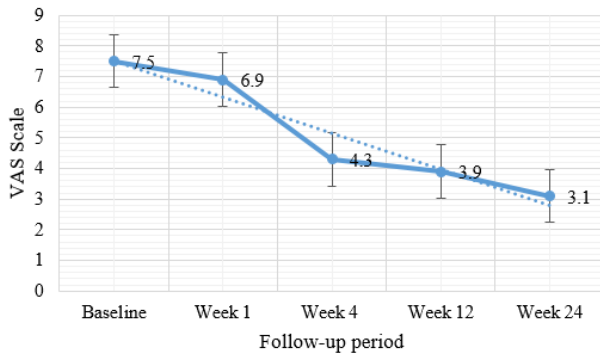
Fig. 1: Showing the functional outcome based on DASH Score

4. Discussion

In sports medicine, the number of injuries occurring due to overuse is about 30-50%.⁶ In general, in physically active individuals, the prevalence of musculoskeletal symptoms increases with the duration of the employment.⁷ Logistic

Table 1: Age-wise distribution of the cases included in the study stratified by diagnosis.

| Pathology | 18-25 yrs. | 26-35 yrs. | 36-45 yrs. | 46-55 yrs. | 56-65 yrs. | Total |
|-----------------------------|------------|------------|------------|------------|------------|-------|
| Supraspinatus Tendinopathy | 6 | 22 | 8 | 6 | 4 | 46 |
| Lateral Epicondylitis | 0 | 5 | 15 | 3 | 0 | 23 |
| Medial Epicondylitis | 0 | 0 | 3 | 1 | 1 | 5 |
| De Quervain's Tenosynovitis | 1 | 2 | 8 | 3 | 0 | 14 |
| Trigger Finger | 0 | 2 | 5 | 0 | 0 | 7 |

**Fig. 2:** Showing the functional outcome based on VAS Score

regression adjusted to the age has shown that people who have worked for 25-35 years are more likely to develop tendinopathy.⁷ The majority of the overuse injuries of the soft tissues and tendons occur in men due to the more vigorous lifestyle/occupations of the majority of the men as compared to that of women.

We have observed in our study that the majority of the injuries occurred in the age group between 36 – 45 years accounting for 41% of the cases with a male preponderance accounting for 63% of the total cases. These findings are substantiated by the study conducted by Hamilton et al.⁸ wherein the majority of the cases of epicondylitis fall in the 35-54 age group and the mean age of incidence was 45 years.

Supraspinatus tendinitis was the predominant diagnosis with 48.4% of the cases diagnosed with the condition. Supraspinatus tendinitis occurred predominantly (22/46) in the 26-35 year age group suggesting repetitive overhead abduction activities in this age group. Wolf et al. and Warner et al.^{9,10} suggested that certain types of sports requiring repetitive use of an arm at or above the horizontal level and during rapid deceleration such as tennis serves, volleyball smashes and javelin throws produce immense stresses and thereby causing overloading, inflammation, and degeneration of the rotator cuff tendons.

Lateral epicondylitis was also observed in 24% of the total cases with most of the patients lying in the age group of 36-45 years (63%) and the distribution was almost equal in both sexes which are also supported by the literature. Gruchow and Pelletier¹¹ reported the incidence of lateral epicondylitis from 31% to 41%. Ciccoti et al¹²

have suggested that the cause of lateral epicondylitis is excessive, monotonous use of the wrist extensors and forearm supinators.

De Quervain's tenosynovitis occurred in 14 of the total cases with a female preponderance with the maximum incidence of the cases occurring in the fourth decade. Werner et al¹³ in their study stated that in physical workers, the incidence of hand and wrist tendinopathies occurs from 4%-56%. The risk is substantially increased when the wrist is exposed to high force, repetition, or vibration. Awkward posturing of the wrist such as ulnar deviation with a fixed thumb, grasping of objects in radial deviation, violent traction, twisting forces supinating or pronating the wrist may also exacerbate the condition.

Trigger finger in our study had an incidence of 7% with the disease again, affecting the patients in the 3rd and 4th decade. Makkouk et al.¹⁴ in their study suggested local trauma and repetitive finger movements and local trauma are the most likely causes leading to degenerative forces causing an increased incidence of triggering in the dominant hand.

Medial epicondylitis had an incidence of 5% in our study with yet again the majority of the patients lying in the 3rd to 4th decade of life. Ciccoti et al¹⁵ in their study could not establish the age and sex predilection of medial epicondylitis due to the infrequent incidence of the condition with an incidence ranging from only 9.8-20%. Degenerative changes in the flexor origin of the medial epicondyle are the result of repetitive eccentric and concentric loading contractile forces of the flexor-pronator muscle groups. Repetitive use although being the primary etiology, a sudden direct blow may also result in medial epicondylitis.

The mean VAS scores decreased consistently with each follow-up with a baseline score of 7.5 and decreasing to 6.9 in the first week, 4.3 in the 4th week, 3.9 in the 12th week, and 3.1 in the final 24th week follow up indicating our results being significant and comparable to other authors. Mishra and Pavelko¹⁶ in their study reported a 60% improvement 8 weeks post-injection in the VAS pain scores. At 6 months post-injection phase they had reported an 80% improvement in their VAS pain score and their final follow-up VAS score was a whopping 93%. Finoff et al.¹⁷ had a mean improvement of 58% in their post-injection VAS scores. Ragab et al.¹⁸ in their study had an improvement in their mean VAS scores from 9.1 to 1.6.

On evaluating the DASH scores of the patients, our mean baseline score was 56.32 and the scores decreased to 31.45 in the first week and 43.58 in the fourth week and progressively decreased to 35.5 and 26.7 in the 12th week and the 24th week respectively. A study conducted by Katana et al.¹⁹ found significant improvement with good functional outcomes in 56% of the patients. But, this study did not take into account the DASH scores. In our study, only a single injection of PRP was infiltrated considering the fact that PRP has the ability to recruit reparative cells.²⁰ This suggests that a single dose of PRP infiltration has a lasting effect on the healing process.

In vitro studies suggest that PRP inhibits interleukin-1 (IL-1) produced by macrophages and thereby reduces their proliferation and in turn the inflammation. PRP also regenerated tissue phenotypically similar to the normal tendon and muscle by stimulating the resting stem cells.²¹ In our study, the double-centrifugation method was used to prepare the PRP. Mautner et al.²² evaluated patients receiving PRP injections and almost 60% required only a single dose, 30% required two doses and only 10% required three or more doses. Gonshor et al.²³ suggested the two-stage technique for processing PRP and had a platelet concentration which was three to five times higher than that of the whole blood baseline, the PDGF-AB was above 500% and the TGF- β 1 was more than 800%.

Our study has a few limitations. The sample size and the follow-up of the included patients were limited. We did not form a control group to estimate the placebo effect due to the treatment procedure.

5. Conclusion

PRP injections are a safe and effective treatment for patients presenting with tendinopathies irrespective of their etiologies and location. All the included patients had a consistent improvement in their clinical symptoms with just a single dose thereby reducing the adverse effects due to chronic use of non-steroidal anti-inflammatory drugs and also minimize the risk of surgeries. None of our patients reported back with recurrence of symptoms for 6 months follow-up. PRP being easily prepared on an outpatient basis makes it convenient for both the surgeon as well as the patient, and it is economical. With the help of USG, the infiltration can be done exactly at the site of the lesion. Surgeons encountering economically burdened patients with tendinopathies can easily treat the painful pathology with just a few milliliters of their platelet concentrate thereby making it a potential contender for being a gold standard in the management of chronic resistant tendinopathies.

6. Conflict of Interest

The authors declare no conflict of interest.

7. Source of Funding

No funding was utilized for the conduction of this study.


References

- Järvinen M. Epidemiology of Tendon Injuries in Sports. *Clin Sports Med*. 1992;11(3):493–504. doi:10.1016/s0278-5919(20)30504-4.
- Kraushaar B, Nirschl R. Current Concepts Review - Tendinosis of the Elbow (Tennis Elbow). Clinical Features and Findings of Histological, Immunohistochemical, and Electron Microscopy Studies*. *J Bone Joint Surg Am*. 1999;81(2):259–78. doi:10.2106/00004623-199902000-00014.
- Eppley BL, Woodell JE, Higgins J. Platelet Quantification and Growth Factor Analysis from Platelet-Rich Plasma: Implications for Wound Healing. *Plast Reconstr Surg*. 2004;114:1502–8. doi:10.1097/01.prs.0000138251.07040.51.
- Sampson S, Gerhardt M, Mandelbaum B. Platelet rich plasma injection grafts for musculoskeletal injuries: a review. *Curr Rev Musculoskelet Med*. 2008;1(3-4):165–74. doi:10.1007/s12178-008-9032-5.
- Molloy T, Wang Y, Murrell GAC. The Roles of Growth Factors in Tendon and Ligament Healing. *Sports Med*. 2003;33(5):381–94. doi:10.2165/00007256-200333050-00004.
- Scott A, Ashe MC. Common Tendinopathies in the Upper and Lower Extremities. *Curr Sports Med Rep*. 2006;5(5):233–41. doi:10.1097/01.csmr.0000306421.85919.9c.
- Forde MS, Punnett L, Wegman DH. Prevalence of Musculoskeletal Disorders in Union Ironworkers. *J Occup Environ Hyg*. 2005;2(4):203–12. doi:10.1080/15459620590929635.
- Hamilton PG, Mrcgp. The prevalence of humeral epicondylitis: A survey in general practice. *J R Coll Gen Pract*. 1986;36:464–5.
- Wolf WB 3rd Shoulder tendinosis. *Clin Sports Med*. 1992;11:871–90.
- Warner JJ, Warren RF. Consideration and management of rotator cuff tears in athletes. *Ann Chir Gynaecol*. 1991;80:160–7.
- Gruchow HW, Pelletier D. An epidemiologic study of tennis elbow. Incidence, recurrence, and effectiveness of prevention strategies. *Am J Sports Med*. 1979;7:234–8.
- Ciccotti MG, Lombardo SJ. Lateral and medial epicondylitis of the elbow. Operative Techniques in Upper Extremity Sports Injuries. St. Louis (MO: Mosby-Year Book; 1996. p. 431–6.
- Werner RA, Franzblau A, Gell N, Ulin SS, Armstrong TJ. A Longitudinal Study of Industrial and Clerical Workers: Predictors of Upper Extremity Tendonitis. *J Occup Rehabil*. 2005;15(1):37–46. doi:10.1007/s10926-005-0872-1.
- Makkouk AH, Oetgen ME, Swigart CR, Dodds SD. Trigger finger: etiology, evaluation, and treatment. *Current Reviews in Musculoskeletal Medicine*. 2008;1(2):92–96. Available from: <https://dx.doi.org/10.1007/s12178-007-9012-1>. doi:10.1007/s12178-007-9012-1.
- Ciccotti MC, Schwartz MA, Ciccotti MG. Diagnosis and treatment of medial epicondylitis of the elbow. *Clin Sports Med*. 2004;23(4):693–705. doi:10.1016/j.csm.2004.04.011.
- Mishra A, Pavelko T. Treatment of Chronic Elbow Tendinosis with Buffered Platelet-Rich Plasma. *Am J Sports Med*. 2006;34(11):1774–8. doi:10.1177/0363546506288850.
- Man D, Plosker H, Winland-Brown JE. The Use of Autologous Platelet-Rich Plasma (Platelet Gel) and Autologous Platelet-Poor Plasma (Fibrin Glue) in Cosmetic Surgery. *Plast Reconstr Surg*. 2001;107(1):229–37. doi:10.1097/00006534-200101000-00037.
- Ragab EM, Othman AM. Platelets rich plasma for treatment of chronic plantar fasciitis. *Arch Orthop Trauma Surg*. 2012;132:1065–70.
- Katana B, Jaganjac A, Bojičić S, Hadžiomerović AM, Pecar M, Kaljić E, et al. Effectiveness of physical treatment at De Quervain's disease. *J Health Sci*. 2012;2(1):80–4. doi:10.17532/jhsci.2012.88.
- Woodall J, Tucci M, Mishra A, Benghuzzi H. Cellular effects of platelet rich plasma: A study on HL-60 macrophage-like cells. *Biomed Sci Instrum*. 2007;43:266–71.

21. Bi Y, Ehrichiou D, Kilts TM, Inkson CA, Embree MC, Sonoyama W, et al. Identification of tendon stem/progenitor cells and the role of the extracellular matrix in their niche. *Nat Med.* 2007;13(10):1219–27. doi:10.1038/nm1630.
22. Mautner K, Colberg R, Malanga G, Borg-Stein JP, Harmon KG, Dharamsi AS, et al. Outcomes After Ultrasound-Guided Platelet-Rich Plasma Injections for Chronic Tendinopathy: A Multicenter, Retrospective Review. *PMR.* 2013;5(3):169–75. doi:10.1016/j.pmrj.2012.12.010.
23. Gonshor A. Technique for producing platelet-rich plasma and platelet concentrate: Background and process. *Int J Periodontics Restor Dent.* 2002;22:547–57.

Author biography

TP Saravanakumar, Assistant Professor

Sathish Muthu, Assistant Orthopaedic Surgeon  <https://orcid.org/0000-0002-7143-4354>

Cite this article: Saravanakumar TP, Muthu S. USG guided platelet rich plasma therapy for chronic resistant tendinopathies – Is it the next gold standard?. *IP Int J Orthop Rheumatol* 2020;6(2):71-75.