

We are IntechOpen, the world's leading publisher of Open Access books Built by scientists, for scientists

6,700

Open access books available

182,000

International authors and editors

195M

Downloads

Our authors are among the

154

Countries delivered to

TOP 1%

most cited scientists

12.2%

Contributors from top 500 universities



WEB OF SCIENCE™

Selection of our books indexed in the Book Citation Index
in Web of Science™ Core Collection (BKCI)

Interested in publishing with us?
Contact book.department@intechopen.com

Numbers displayed above are based on latest data collected.
For more information visit www.intechopen.com



“Hidden Lesions of the Knee”: Meniscal Ramp Lesions

Iffath Misbah, Girinivasan Chellamuthu and Munis Ashraf

Abstract

Meniscal RAMP lesions are not uncommon with ACL injuries and their incidence is higher in young males sustaining non-contact injuries. Diagnosis requires awareness of the lesion, and its hidden location and how to access it on arthroscopy remain the gold standard in detecting these tears. Despite trials to explain RAMP lesions by signal changes on MR imaging, a correlation was built in only one third of the cases. The healing potential along with the effect on knee stability of RAMP lesions is the reason behind repairing them. In this chapter, we intend to outline the description, incidence, effects, diagnosis and treatment outcomes of these lesions.

Keywords: RAMP, hidden lesions, MRI, treatment, rehabilitation

1. Introduction

The ramp in the posteromedial knee, the so-called because of its sheer resemblance to the ramps that we use to climb, is not a new structure to be described. However, there is a sudden surge in interest in addressing the lesions in this area—called the Ramp lesions. These lesions were described as early as 1983 by Hamberg et al. [1, 2]. Michael J. Strobel invented the term “Ramp lesion” to describe this disorder. He says that a meniscal injury known as a “ramp lesion,” which obliterates the posterior horn of the medial meniscus’s peripheral connection, commonly occurs in conjunction with an ACL tear [3].

Despite being a recognized entity for many years, these lesions were not considered important until recent years. The reasons are that these are the commonly missed lesions unless one is very particular—be it arthroscopically or in the MRIs. The knee is kept extended during the bulk of MRI processes. Ramp lesions are more difficult to analyse in this position because there is less space on the posterior and medial sides. One should be aware of the associated signs of ramp lesions like posteromedial tibial bone bruises. During the routine diagnostic arthroscopy of the knee, as emphasized by Sonnery-Cottet and his colleagues, 40 percent of these injuries are missed out. Only a trans-notch view may show these rips, allowing for a thorough assessment of the posteromedial compartment and a determination of the mobility of the posterior horn of the medial meniscus [4]. These characteristics have paved the way for these lesions to be called “hidden lesions” ultimately making them “forgotten lesions” for several years.

Since ACL reconstructions are among the most common knee operations, there has recently been a global search for surgical perfection. Due to recent research that

suggests ramp lesions contribute to anterior and rotational stability, interest in them has been revived [5, 6].

The definition of Ramp lesions varies in the literature. But generally, they are described as longitudinal or oblique superior meniscocapsular junction tears or the tears in the meniscotibial ligament that typically occur in association with the ACL tears [4, 7]. These mediolateral tears are generally less than 2 cm [8].

2. Anatomy

The meniscotibial ligament attaches to the medial meniscus anteriorly, while the meniscocapsular expansion, also known as the meniscocapsular ligament, attaches to the medial meniscus posteriorly. Knowing the length of this area as well as how the meniscotibial ligaments and meniscocapsular junction adhere to the medial meniscus's back is absolutely crucial.

Based on its capsular attachment and degree of movement, the medial meniscus has been subdivided into a number of zones [9, 10]. The anterior root, also known as zone 1, the anteromedial zone, also known as zone 2, the medial zone, also known as zone 3, the Ramp area also known as zone 4 and the posterior zone, also known as zone 5, were the five zones identified by Smigielski et al. The band of fibrous connective tissue known as the meniscotibial ligament, commonly referred to as the coronary ligament, holds the meniscus to the tibia 7–10 mm below the articular surface, and the meniscotibial ligament is attached to the tibia. As a result of this association, a depression in the posterior femur develops at this location. These results contradict what was previously described for the ramp region by Diphillipo et al. [11]. The posterior zone of the medial meniscus contains descriptions of several attachments to the meniscocapsular and meniscotibial structures. The meniscocapsular ligament, also known as the meniscocapsular attachment, was 20.2 +/- 6 mm on average in length. This attachment was said to become conjoint with the meniscotibial ligament. Above the meniscocapsular ligament and below the superior border of the meniscus, this unified tissue joins to the posterior horn of the medial meniscus, creating a depression above the meniscus. This corresponds to the description of the posterior femoral recess by Smigielski et al. Implications for clinical practice arise from the fact that the ramp area may be reconnected to the posterior capsule after all-inside device repair of ramp lesions, thus bypassing the posterior femoral recess.

Because of its importance in ramp lesion pathophysiology, the architecture of the semimembranosus muscle, and more specifically its distal insertion, must be understood in order to grasp the mechanics of ramp lesions. The semimembranosus has its origin in the upper lateral facet of the ischial tuberosity. It has a complex insertion distally, described variedly across the literature. It is said to have 4 to 8 insertions. There are descriptions of three constant insertions. The lateral collateral ligament attaches inferiorly to the posteromedial tibia, anteriorly to the medial collateral ligament, and laterally to the oblique popliteal ligament and other anteromedial knee tissues, such as the medial meniscus [12]. The SANTI group also noticed the Semimembranosus Capsular Branch, which connects the semimembranosus muscle to the posterior capsule of the knee [13]. This capsular limb is important for understanding the mechanics of ramp fractures. In the literature, it has been reported that the semimembranosus tendon does not directly pass through the posterior horn of the medial meniscus. At best, there is a shaky connection between them. The meniscotibial ligament and meniscocapsular ligament are joined by the tendon's capsular

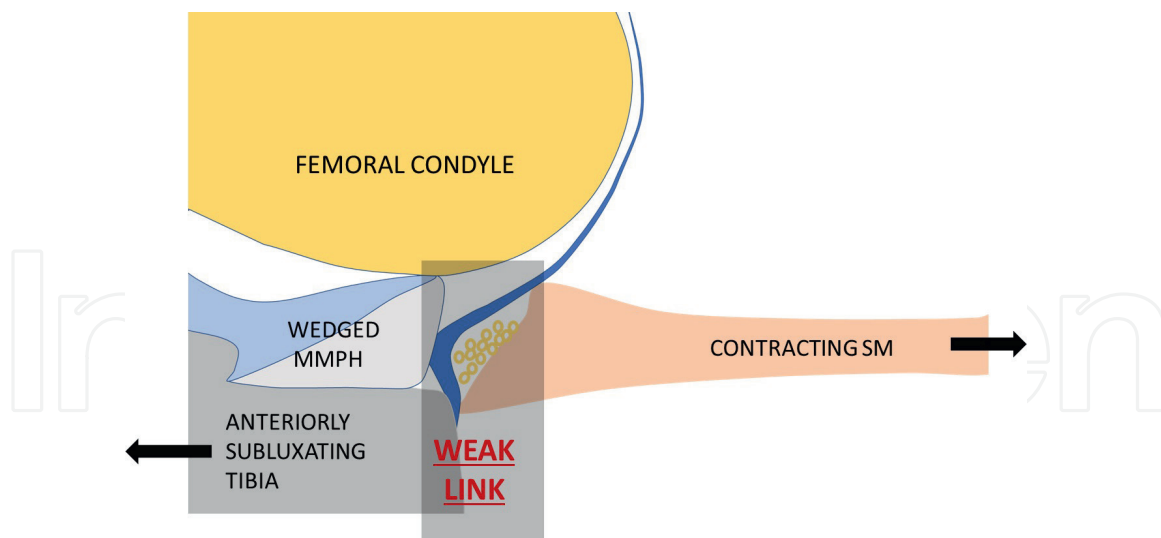


Figure 1.
Anatomy of the ramp.

limb, which connects to the medial meniscus's posterior horn. Ample adipose tissue with its own network of blood arteries was also found in this layer. This weak link is hypothesized to be the cause of ramp lesions. The well-vascularized nature might be implicated in the good healing potential of this region (**Figure 1**) [13].

3. Biomechanics

In addition to increasing anterior stability, the ramp area of the knee seems to aid in the joint's rotational stability [14, 15]. Medial meniscus longitudinal peripheral tear was associated with greater tibial anterior translation in ACL-deficient knees, as reported by Ahn et al. [16]. This improved significantly after the repair of such tears. However, there was no significant change in rotatory stability. According to Peltier et al. [5], there were no discernible changes in anterior translation between ACL-deficient knees, ACL-deficient knees with ramp lesions and ACL-deficient knees with a detached meniscotibial ligament. In ACL-deficient and ACL-deficient with detached meniscotibial ligament knees, internal and external rotation increased considerably under 5-Nm torque, respectively. After severing the meniscocapsular ligament, knees missing a posterior cruciate ligament were more prone to anterior translation and external rotation [17]. One additional clinical study [6] found a stronger correlation between combined ACL and ramp lesions and a grade III pivot test than between grade III pivot tests and isolated ACL tears.

4. Epidemiology

Most often, ACL tears go in conjunction with ramp lesions. Ramp lesions co-occurring with ACL tears have a frequency of somewhere between 9% [18] and 42% [19]. The incidence increase when the delay of ACL reconstruction is more than 3 months [20]. Jiang et al. [21] described 20 cases of ramp lesions over 2-year period without complete ACL tears. They noted ACL longitudinal splits in all these cases. They proposed that these longitudinal splits would have resulted in minimal anterior instability leading to

ramp lesions due to semimembranosus contraction. Due to their invisibility on MRI and during arthroscopy [22, 23], the real prevalence of ramp lesions is unknown. These lesions may occur on their own or in conjunction with ACL tears. Ramp lesions have a same prevalence in both adults and children. Meniscal tears are more prevalent in children and teenagers; therefore, this is in sharp contrast to the general population [24].

5. Pathophysiology

The tibia shifts abnormally toward the front after an ACL injury. As a consequence of this stimulation, the semimembranosus muscle contracts, resulting in elongation of the capsular arm, meniscocapsular ligament and meniscotibial ligament. If the medial meniscus becomes trapped between the articular surfaces, a tear can develop if the ramp area gives way [13, 25, 26].

There have also been identified other ramp lesion development mechanisms. The most basic is the stress an ACL tear [27] places on the posteromedial joint capsule, which results in a valgus injury with internal rotation and axial loading of the tibia. A contrecoup injury can develop from a ramp lesion when the knee recovers from pivoting due to a varus strain and internal rotation of the femur on the tibia [28]. This technique results in a ramp rip in the medial meniscus by pressing it on the articular cartilages of the femur and tibia (**Figure 2**).

6. Clinical features

With these injuries, the anterior cruciate ligament (ACL) is frequently torn. Some of the clinical features that are indicative of the probable presence of ramp lesions include chronic ACL injuries of more than 3 months, a varus knee of more than 3 degrees [29], increased anterior tibial translation [18] and a grade III pivot test result [6]. A multivariate analysis of 769 ramp repairs found that ACL injury in the age group of fewer than 30 years had increased chances of developing ramp

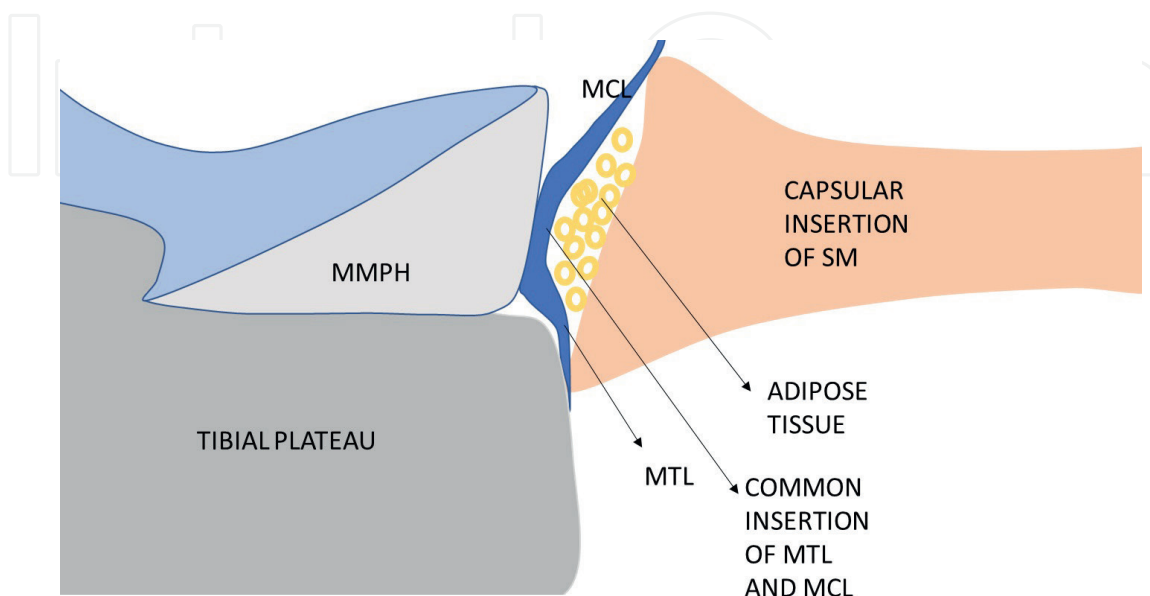


Figure 2.
Pathomechanics of RAMP lesion.

lesions. Males had 1.5 times increased risk of developing ramp lesions when compared to females. There is a strong correlation between the existence of a ramp lesion and a laxity difference of more than 6 mm from side to side [30]. A concomitant anterolateral ligament injury also increases the chances of ramp lesion [31]. Isolated ramp lesions, which are rare, present with posteromedial knee pain and pain on deep flexion [21].

7. Imaging diagnosis

On the other side, ramp lesions may be detected using the more common MR imaging of the knee. Injuries to ligaments and soft tissues may be treated with success using certain flexed-knee and/or 3D sequences (**Figure 3**) [22, 32].

Studies show that meniscal ramp lesions may be found using magnetic resonance imaging (MRI), which is both extremely sensitive and specific. Specificity was found to be 92–98% by Arner et al. [33], whereas sensitivity ranged from 53 to 84%. This sensitivity was observed by DePhillipo et al. [34]: The sensitivity and specificity of the meta-analyses and systematic review conducted by Koo et al. [35] were 71 and 94, respectively.

Hatayama et al. and Yeo et al. discovered that 3.0-T MRI was more capable of detecting ramp lesions than 1.5-T MRI [36]. By detecting an abnormality at the posterior border and complete fluid filling, ramp lesions may be accurately identified on MRI. While successive sagittal images may be utilized to pinpoint the damaged areas

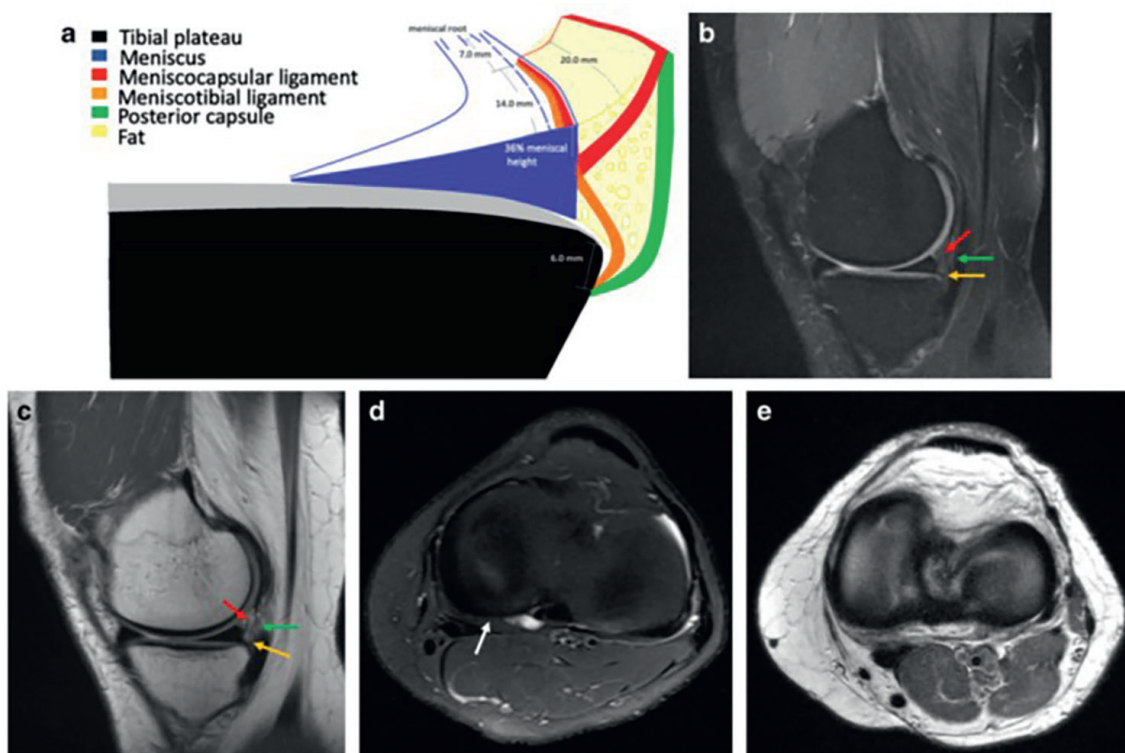


Figure 3. *a–e* Normal composition. *b*. Any evidence of perimeniscal fluid separation was not seen during the sagittal proton density fat-suppression investigation. *c*. Fat signal intensity around the meniscocapsular junction is seen in a sagittal proton density image. Meniscotibial ligament, meniscocapsular ligament and posterior capsule (red arrow, green arrow) (orange arrow). *d*. Axial proton density fat saturation research found no evidence of perimeniscal fluid separation (white arrow). *e*. Proton density along the shaft.

	MRI findings pointing to the existence of a meniscal ramp lesion	MRI results indicating an absence of a meniscal ramp lesion
Primary findings	<ol style="list-style-type: none"> 1. High T2 fluid signal intensity along the longitudinal, mediolateral, vertical and/or oblique axes, extending anteriorly, inferiorly or to both articular surfaces between the posterior horns of the medial meniscus and the posteromedial capsule. 2. Meniscocapsular attachment defects, which manifest as a localized discontinuity or a step-like contour distortion in the back of the knee, are caused by irregularities along the posterior margin of the medial meniscus. 3. Perimeniscal fluid's posteromedial corner of the knee's signal strength. 4. Soft tissue has grown between the medial meniscus and the medial collateral ligament. 	<ol style="list-style-type: none"> 1. Intact ACL. 2. When the red-red zone in the medial meniscus's posterior horn and the meniscotibial ligaments are present, the posteromedial meniscocapsular attachment is regarded as complete. 3. Medial and lateral meniscus linear T2 rips that do not impact the meniscotibial ligaments or attachments or extend past the red-red zone.
Secondary findings	<ol style="list-style-type: none"> 1. Findings that indicate to simultaneous ACL damage: Tibial bone marrow edema with a posterior-medial distribution, consistent with a simultaneous contrecoup injury. <ul style="list-style-type: none"> • Transchondral fracture is found • The posterior cruciate ligament is harmed as a consequence of the lateral meniscus's back being exposed. • Utilizing a single coronal image to visualize the fibular collateral ligament • In relation to the lateral femoral condyle, the lateral tibial plateau grows forward. 	<ol style="list-style-type: none"> 1. No evidence of an associated ACL damage was found.

Table 1.
Summary of positive and negative findings for ramp lesions.

of the meniscocapsular junction and posterior horn, alternating sagittal and axial views can be used to assess the mediolateral and mediolateral dimensions of lesions [37, 38]. In **Table 1** we have compiled a summary of the MRI results, both favourable and negative.

8. Classifications

Meniscal ramp lesions have only been classified in the following few ways (**Table 2**).

- To evaluate whether a tear is adherent (self-heal) or dehiscent, adherent vs. dehiscent, and mediolateral vs. lateral, Seil et al. [39] analysed a set of cadaveric knees (repair).
- Instability, tear pattern, tear direction, tear thickness (partial vs. whole) and meniscocapsular disruption were all investigated by Thauinat et al. [40] in relation to meniscotibial ligament injuries.

Thannaut et al.		Grief et al.	
Ramp lesions type	Arthroscopic stability finding	Ramp lesions type	Arthroscopic stability finding
Type 1: Meniscocapsular tear	Stable	Type 1: Meniscocapsular ligament tear	Stable
Type 2: Partial superior tear	Stable	Type 2: Partial superior peripheral meniscal horn tear	Stable
Type 3: Partial inferior tear	Unstable	Type 3A: Partial inferior peripheral posterior horn meniscal tear	Unstable
Type 4: Complete tear	Unstable	Type 3B: Meniscotibial ligament tear	Unstable
Type 5: Double tear	Unstable	Type 4A: Complete peripheral posterior horn meniscal tear	Unstable
		Type 4B: Complete meniscojunction tear	Unstable
		Type 5: Peripheral posterior horn meniscal double tear	Unstable

Table 2.
 Classification systems in RAMP lesions.

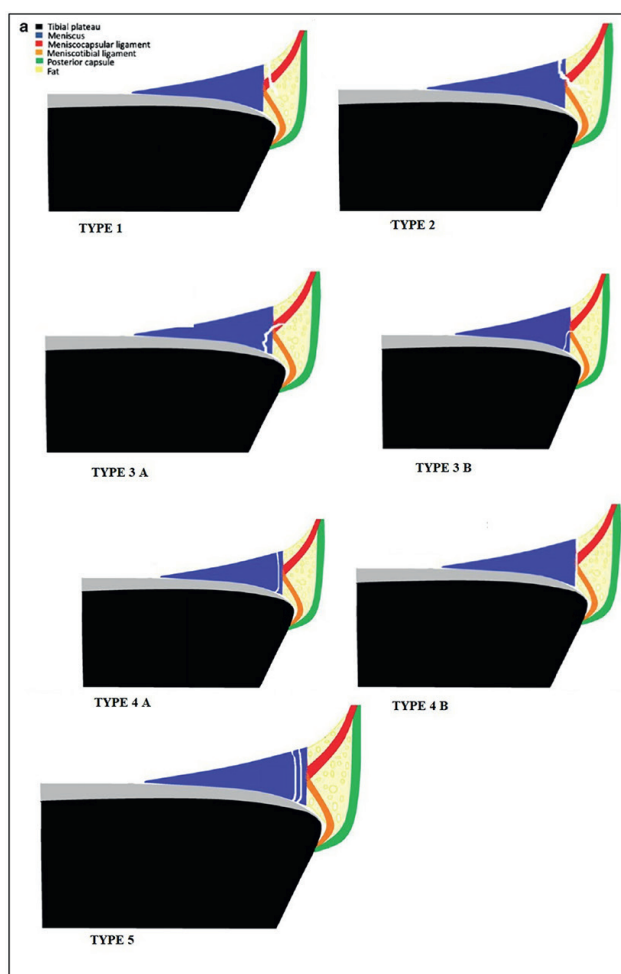


Figure 4.
 Thaunat classification for ramp lesions.

- The Thaunat classification has been upgraded by Greif et al. [41] based on recent cadaveric investigations that support the union of the meniscocapsular and meniscotibial ligaments at the posterior horn meniscal connection (**Figure 4**).

9. Treatment

Meniscal ramp lesions have no consented treatment at the present time. Research has shown that ramp lesions in the context of acute ACLR may recover without surgical intervention if the surrounding biological conditions are appropriate. Some have suggested that ramp lesions should be surgically addressed rather than being let to heal on its own due to the hypermobility of the separated meniscocapsular component. There is data to suggest that individuals with similar longitudinal meniscal tear patterns who have ACLR without first having surgery may benefit from nonsurgical treatment. This is against the general view that ramp lesions should be addressed when there is chronic ACL insufficiency [16].

9.1 Repair procedure

For meniscal ramp lesions, when repair is the preferred therapy, the anatomic position of the lesion might provide a technical problem. The saphenous neurovascular bundle is at danger if a lesion in the posteromedial area of the knee is attempted to be treated. Repairing a ramp lesion requires careful attention to the saphenous nerve, therefore inside-out approaches should be utilized with caution and direct sight of the posterior capsule is preferred. Both inward-focused and outward-focused strategies have been effective in dealing with this issue. There is more room for movement when using sutures in an inside-out repair, which may lead to a more robust structure overall.

In the posteromedial technique for the inside-out repair, an incision is made vertically and obliquely from the adductor tubercle to the rear of the tibial plateau. The anatomical “triangle” formed by the medial gastrocnemius to the back, the inferior direct arm of the semimembranosus to the inferior and the anterior posteromedial joint capsule to the anterior may be seen after making a proximal incision in the soleus muscle fascia while keeping the pes anserine tendons *in situ*. The posterior neurovascular systems are shielded by a retractor while the wound is healing.

Using an arthroscopic self-delivery pistol with a cannula, double-loaded, non-absorbable sutures are placed into the meniscus in a mattress-like vertical pattern. The medial meniscal needle is placed into the upper or lower portion of the posterior horn of the medial meniscus with the knee flexed at an angle of 20 to 30 degrees. The meniscofemoral or meniscotibial capsule's opening is entered with the suture's second needle. Light pressure is used while clamping the suture ends. Another round of sutures, this time separated by 3–5 mm is used to complete the procedure. It is best to avoid putting too much weight on the posteromedial tissues while tying the meniscal sutures with the knee flexed at a 90-degree angle.

On the other hand, we may use methods that take place entirely inside the patient's body. While the advantages of these methods in terms of user friendliness and reduced neurovascular risks are undeniable, they are not without their share of drawbacks, including, but not limited to, discomfort from anchors, and meniscal body rips as a result of the larger holes formed by device insertion. The stages of the repair procedure will be different depending on the tool.

However, there is currently no agreed-upon surgical rehabilitation programme for meniscal ramp injuries. Rehabilitation plans should start with broad concepts and be modified for each patient. In addition, when a meniscal ramp lesion and another knee injury occur simultaneously, the rehabilitation will be influenced in part by the simultaneous surgical operation.

10. Rehabilitation

Whether the meniscal ramp lesion treatment is an independent procedure or done at the same time as an ACL restoration affects the rehabilitation strategy. When an ACL reconstruction is done, the patient must undergo rehabilitation as outlined in the ACL rehabilitation protocol. On the first postoperative day, a patient who has undergone an isolated meniscal ramp repair should start performing exercises to reduce edema, improve knee range of motion, and develop the quadriceps. In the early postoperative phase, weightbearing and knee flexion are limited to minimise excessive stress on the repair. Maximum knee flexion activities (such as squatting and lifting) and pivotal and contact sports should be avoided for 4 to 6 months [42].

In average, patients who undergo repairs of tears to the outer two-thirds of the meniscus, such as ramp lesions, recover more quickly than those who have meniscal transplants or repairs of tears to the centre one-third of the meniscus. When a patient has a non-tender joint line, no pain or effusion, total muscle strength and full range of motion, particularly in full extension, they are prepared to resume sports or strenuous activities.

11. Conclusion

When it comes to ACL-deficient knees, ramp lesions are widespread yet sometimes ignored, especially in the acute situation. In ACL-deficient knees, these tears may induce substantial anterior tibial translation and external rotational instability, which can only be restored by performing a concurrent meniscal repair in addition to an ACL reconstruction. Ramp lesions are notoriously challenging to identify on MRI; hence, a thorough arthroscopic approach is often required for accurate diagnosis. Repairing ramp lesions is highly suggested if they are present to prevent negative biomechanical effects. Isolated ramp lesions should be treated with the same technique used for meniscal repair after rehabilitation as other knee injuries. However, if an ACL repair is done at the same time, recovery should adhere to the postoperative protocol for ACL reconstruction. Understanding about this injury type is essential, especially in the setting of an ACL tear, as ramp tears are more often than previously thought.

IntechOpen

Author details

Iffath Misbah¹, Girinivasan Chellamuthu² and Munis Ashraf^{3*}


1 Department of Radiodiagnosis, Saveetha Medical College Hospital, SIMATS University Thandalam, Chennai, India

2 Faculty of Research Karpagam Academy of Higher Education, Coimbatore, India

3 Department of Orthopedic Surgery, Saveetha Medical College Hospital, SIMATS University Thandalam, Chennai, India

*Address all correspondence to: munis6@gmail.com

IntechOpen

© 2023 The Author(s). Licensee IntechOpen. This chapter is distributed under the terms of the Creative Commons Attribution License (<http://creativecommons.org/licenses/by/3.0>), which permits unrestricted use, distribution, and reproduction in any medium, provided the original work is properly cited. 

References

- [1] Hamberg P, Gillquist J, Lysholm J. Suture of new and old peripheral meniscus tears. *JBJS*. 1983;65(2):193
- [2] Sonnery-Cottet B, Cruz RS, Vieira TD, Goes RA, Saithna A. Ramp lesions: An unrecognized posteromedial instability? *Clinics in Sports Medicine*. 2020;39(1):69-81
- [3] Strobel M. *Manual of Arthroscopic Surgery*. New York: Springer; 1988
- [4] Sonnery-Cottet B, Conteduca J, Thaunat M, Gunepin FX, Seil R. Hidden lesions of the posterior horn of the medial meniscus: A systematic arthroscopic exploration of the concealed portion of the knee. *The American Journal of Sports Medicine*. 2014;42(4):921-926
- [5] Peltier A, Lording T, Maubisson L, Ballis R, Neyret P, Lustig S. The role of the meniscotibial ligament in posteromedial rotational knee stability. *Knee Surgery, Sports Traumatology, Arthroscopy: Official Journal of the ESSKA*. 2015;23(10):2967-2973
- [6] Mouton C, Magosch A, Pape D, Hoffmann A, Nührenbörger C, Seil R. Ramp lesions of the medial meniscus are associated with a higher grade of dynamic rotatory laxity in ACL-injured patients in comparison to patients with an isolated injury. *Knee Surgery, Sports Traumatology, Arthroscopy: Official Journal of the ESSKA*. 2020;28(4):1023-1028
- [7] Śmigielski R, Becker R, Zdanowicz U, Cizek B. Medial meniscus anatomy—from basic science to treatment. *Knee Surgery, Sports Traumatology, Arthroscopy: Official Journal of the ESSKA*. 2015;23(1):8-14
- [8] Taneja AK, Miranda FC, Rosemberg LA, Santos DCB. Meniscal ramp lesions: An illustrated review. *Insights Into Imaging*. 2021;12(1):134
- [9] Yagishita K, Muneta T, Ogiuchi T, Sekiya I, Shinomiya K. Healing potential of meniscal tears without repair in knees with anterior cruciate ligament reconstruction. *The American Journal of Sports Medicine*. 2004;32(8):1953-1961
- [10] Wymenga AB, Kats JJ, Kooloos J, Hillen B. Surgical anatomy of the medial collateral ligament and the posteromedial capsule of the knee. *Knee Surgery, Sports Traumatology, Arthroscopy: Official Journal of the ESSKA*. 2006;14(3):229-234
- [11] DePhillipo NN, Moatshe G, Chahla J, Aman ZS, Storaci HW, Morris ER, et al. Quantitative and qualitative assessment of the posterior medial meniscus anatomy: Defining meniscal ramp lesions. *The American Journal of Sports Medicine*. 2019;47(2):372-378
- [12] Benninger B, Delamarter T. Distal semimembranosus muscle-tendon-unit review: Morphology, accurate terminology, and clinical relevance. *Folia Morphologica*. 2013;72(1):1-9
- [13] Cavaignac E, Sylvie R, Teulières M, Fernandez A, Frosch K-H, Gomez-Brouchet A, et al. What is the relationship between the distal semimembranosus tendon and the medial meniscus? A gross and microscopic analysis from the SANTI study group. *The American Journal of Sports Medicine*. 2021;49(2):459-466
- [14] Papageorgiou CD, Gil JE, Kanamori A, Fenwick JA, Woo SL-Y, Fu FH. The biomechanical interdependence between the anterior cruciate ligament replacement

graft and the medial meniscus. *The American Journal of Sports Medicine*. 2001;**29**(2):226-231

[15] DePhillipo NN, Moatshe G, Brady A, Chahla J, Aman ZS, Dornan GJ, et al. Effect of Meniscocapsular and Meniscotibial lesions in ACL-deficient and ACL-reconstructed knees: A biomechanical study. *The American Journal of Sports Medicine*. 2018;**46**(10):2422-2431

[16] Ahn JH, Bae TS, Kang K-S, Kang SY, Lee SH. Longitudinal tear of the medial meniscus posterior horn in the anterior cruciate ligament-deficient knee significantly influences anterior stability. *The American Journal of Sports Medicine*. 2011;**39**(10):2187-2193

[17] Stephen JM, Halewood C, Kittl C, Bollen SR, Williams A, Amis AA. Posteromedial Meniscocapsular lesions increase Tibiofemoral joint laxity with anterior cruciate ligament deficiency, and their repair reduces laxity. *The American Journal of Sports Medicine*. 2016;**44**(2):400-408

[18] Tashiro Y, Mori T, Kawano T, Oniduka T, Arner JW, Fu FH, et al. Meniscal ramp lesions should be considered in anterior cruciate ligament-injured knees, especially with larger instability or longer delay before surgery. *Knee Surgery, Sports Traumatology, Arthroscopy*. 2020;**28**(11):3569-3575

[19] Balazs GC, Greditzer HG, Wang D, Marom N, Potter HG, Marx RG, et al. Ramp lesions of the medial meniscus in patients undergoing primary and revision ACL reconstruction: Prevalence and risk factors orthopaedic. *Journal of Sports Medicine*. 2019;**7**(5):2325967119843509

[20] Keyhani S, Esmailiejah AA, Mirhoseini MS, Hosseinijad S-M,

Ghanbari N. The prevalence, zone, and type of the meniscus tear in patients with anterior cruciate ligament (ACL) injury; does delayed ACL reconstruction affects the meniscal injury? *Archives of Bone and Joint Surgery*. 2020;**8**(3):432-438

[21] Jiang J, Ni L, Chen J. Isolated meniscal ramp lesion without obvious anterior Cruciate ligament rupture. *Orthopaedic Surgery*. 2021;**13**(2):402-407

[22] Okazaki Y, Furumatsu T, Okamoto S, Hiranaka T, Kintaka K, Miyazawa S, et al. Diagnostic performance of open MRI in the flexed knee position for the detection of medial meniscus ramp lesions. *Skeletal Radiology*. 2020;**49**(11):1781-1788

[23] Peltier A, Lording TD, Lustig S, Servien E, Maubisson L, Neyret P. Posteromedial meniscal tears may Be missed during anterior cruciate ligament reconstruction. *Arthroscopy: The Journal of Arthroscopic & Related Surgery*. 2015;**31**(4):691-698

[24] Malatray M, Raux S, Peltier A, Pfirrmann C, Seil R, Chotel F. Ramp lesions in ACL deficient knees in children and adolescent population: A high prevalence confirmed in intercondylar and posteromedial exploration knee surgery. *Sports Traumatology, Arthroscopy*. 2018;**26**(4):1074-1079

[25] Qalib YO, Tang Y, Wang D, Xing B, Xu X, Lu H. Ramp lesion of the medial meniscus. *EFORT Open Reviews*. 2021;**6**(5):372-379

[26] Hughston JC. *Knee Ligaments: Injury & Repair*. 1993. pp. 300-315

[27] Young R, Devitt BM, Whitehead T. Meniscal ramp lesions: Diagnosis and treatment strategies. In: LaPrade RF, Arendt EA, Getgood A, Faucett SC, editors. *The Menisci: A Comprehensive Review of their Anatomy*. Biomechanical

Function and Surgical Treatment Berlin, Heidelberg: Springer; 2017. pp. 63-75

2017;**25**:3955-3960. DOI: 10.1007/s00167-017-4523-9

[28] Yoon KH, Yoo JH, Kim K-I. Bone contusion and associated meniscal and medial collateral ligament injury in patients with anterior cruciate ligament rupture. *The Journal of Bone and Joint Surgery*. 2011;**93**(16):1510

[34] DePhillipo NN, Cinque ME, Chahla J, et al. Incidence and detection of meniscal ramp lesions on magnetic resonance imaging in patients with anterior cruciate ligament reconstruction. *The American Journal of Sports Medicine*. 2017;**45**:2233-2237. DOI: 10.1177/0363546517704426

[29] Kim SH, Seo HJ, Seo DW, Kim K-I, Lee SH. Analysis of risk factors for ramp lesions associated with anterior cruciate ligament injury. *The American Journal of Sports Medicine*. 2020;**48**(7):1673-1681

[35] Koo B, Lee SH, Yun SJ, Song JG. Diagnostic performance of magnetic resonance imaging for detecting meniscal ramp lesions in patients with anterior cruciate ligament tears: A systematic review and metaanalysis. *The American Journal of Sports Medicine*. 2020;**48**:2051-2059. DOI: 10.1177/0363546519 880528

[30] Sonnery-Cottet B, Praz C, Rosenstiel N, Blakeney WG, Ouanezar H, Kandhari V, et al. Epidemiological evaluation of meniscal ramp lesions in 3214 anterior cruciate ligament-injured knees from the SANTI study group database: A risk factor analysis and study of secondary meniscectomy rates following 769 ramp repairs. *The American Journal of Sports Medicine*. Nov 2018;**46**(13):3189-3197

[36] Hatayama K, Terauchi M, Saito K, et al. Magnetic resonance imaging diagnosis of medial meniscal ramp lesions in patients with anterior cruciate ligament injuries. *Arthroscopy: The Journal of Arthroscopic & Related Surgery*. 2018;**34**:1631-1637. DOI: 10.1016/j.arthro.2017.12.022

[31] Ahn JH, Lee SK, Mun JW, Kim SW. Degree of anterolateral ligament injury impacts outcomes after double-bundle anterior cruciate ligament reconstruction. *Arthroscopy: The Journal of Arthroscopic & Related Surgery*. 2021;**37**(1):222-230

[37] Yeo Y, Ahn JM, Kim H, et al. MR evaluation of the meniscal ramp lesion in patients with anterior cruciate ligament tear. *Skeletal Radiology*. 2018;**47**:1683-1689. DOI: 10.1007/s00256-018-3007-4

[32] Taneja AK, Miranda FC, Demange MK, et al. Evaluation of posterior cruciate ligament and intercondylar notch in subjects with anterior cruciate ligament tear: A comparative flexed-knee 3D magnetic resonance imaging study. *Arthroscopy*. 2018;**34**:557-565. DOI: 10.1016/j.arthro.2017.08.296

[38] Laurens M, Cavaignac E, Fayolle H, Sylvie R, Lapègue F, Sans N et al. The accuracy of MRI for the diagnosis of ramp lesions. *Skeletal Radiology*. Mar 2022;**51**(3):525-533

[33] Arner JW, Herbst E, Burnham JM, et al. MRI can accurately detect meniscal ramp lesions of the knee. *Knee Surgery, Sports Traumatology, Arthroscopy*.

[39] Seil R, Hoffmann A, Scheffler S, et al. Ramp lesions: Tips and tricks in diagnostics and therapy. *Orthopäde*. 2017;**46**:846-854. DOI: 10.1007/s00132-017-3461-z

[40] Thauinat M, Fayard JM, Guimaraes TM, et al. Classification and surgical repair of ramp lesions of the medial meniscus. *Arthroscopy Techniques*. 2016;5:e871-e875. DOI: 10.1016/j.eats.2016.04.009

[41] Greif DN, Baraga MG, Rizzo MG, et al. MRI appearance of the different meniscal ramp lesion types, with clinical and arthroscopic correlation. *Skeletal Radiology*. 2020;49:677-689. DOI: 10.1007/s00256-020-03381-4

[42] Chahla J, Dean CS, Moatshe G, Mitchell JJ, Cram TR, Yacuzzi C, et al. Meniscal ramp lesions: Anatomy, incidence, diagnosis, and treatment. *Orthopaedic Journal of Sports Medicine*. 2016;4(7):2325967116657815