


Contents lists available at [ScienceDirect](https://www.sciencedirect.com)

Journal of Orthopaedic Reports

journal homepage: www.journals.elsevier.com/journal-of-orthopaedic-reports

Paediatric lumbar disc herniation presenting as pseudo flexion deformity of the hip and knee: A case report

Rajni Ranjan^a, Satvik N. Pai^b, Sathish Muthu^c, Madhan Jeyaraman^{d,*}

^a Department of Orthopaedics, School of Medical Sciences and Research, Sharda University, Greater Noida, Uttar Pradesh, India

^b Department of Orthopaedics, Sri Ramachandra Institute of Higher Education and Research, Chennai, Tamil Nadu, India

^c Department of Orthopaedics, Government Medical College and Hospital, Dindigul, Tamil Nadu, India

^d Department of Orthopaedics, Faculty of Medicine, Sri Lalithambigai Medical College and Hospital, Dr MGR Educational and Research Institute, Chennai, Tamil Nadu, India

ARTICLE INFO

Keywords:

Lumbar disc
Herniation
Interlaminar discectomy
Spine
Paediatric

ABSTRACT

Background: Lumbar disc herniation (LDH) in paediatric age group is rare and respond differently to treatment measures compared to adult LDH. We present such a case with an atypical and confusing presentation.

Case report: A 13-year-old boy presented with radiating low back pain for two weeks, and a pseudo flexion deformity of the hip and knee. The bowstring sign was positive, the sensory loss was present over the S1 dermatome, and an ankle jerk was absent. MRI showed disc herniation and annulus fibrosis tear at the L5-S1 level. Right interlaminar discectomy of L5-S1 provided a complete resolution of symptoms, and excellent functional outcome at two years follow up.

Conclusion: A disc herniation should be considered as a differential diagnosis in children presenting with back pain. Pseudo flexion deformity of hip and knee could be an indicator of S1 nerve root compression. Paediatric LDH responds poorly to conservative management, but a good functional outcome can be achieved with prompt surgical management.

1. Introduction

Lumbar disc herniation (LDH) occurring in the paediatric age group is rare with children constituting only 0.5–3% of the surgically treated lumbar disc herniations.¹ Being an uncommon condition, there is often a delay in diagnosis and appropriate treatment.² The management of paediatric LDH is challenging and it responds differently from adult LDH. Paediatric LDH is often resistant to non-surgical measures.³ The common presentation include radicular pain, back pain, motor weakness, sensory disturbances, and rarely bladder involvement.⁴ We present a case of LDH in a 13-year-old boy with an atypical presentation of pseudo flexion deformity of the hip and knee.

2. Case report

A 13-year-old male child had complained of severe low back pain for two weeks. The pain was radiating to bilateral lower limbs, with it being worse on the right side. The pain had made it difficult for him to be able to walk, forcing him to mostly lay in bed with his hip and knees bent for

the past 5 days. He also experienced urinary hesitancy. He had a history of lifting heavy weights two weeks before the onset of pain. He had no previous medical conditions.

2.1. Clinical findings

On examination, his anthropometric measurements and systemic examination were found to be within normal limits. No neurocutaneous markers were discernible. His attitude was found to be flexion at the hip of 70° and knee flexion of 90° as shown in Fig. 1. Any attempt of extension of hip/knee from this posture was associated with excruciating pain. A hamstring muscle spasm was found to be present. Examination of the spine revealed loss of lumbar lordosis, lumbosacral spinal tenderness and paraspinal muscle spasm. We were unable to assess for the Straight Leg Raising Test as an extension at the hip was not possible. The bowstring sign was found to be positive. The partial sensory loss was present over the lateral aspect of the right foot and leg corresponding to the S1 dermatome. No motor deficits were noted. Ankle jerk was found to be absent on the right side, with other reflexes being intact and flexor plantar response.

* Corresponding author.

E-mail address: madhanjeyaraman@gmail.com (M. Jeyaraman).

<https://doi.org/10.1016/j.jorep.2022.03.010>

Available online xxx

2773-157X/© 2022 The Author(s). Published by Elsevier B.V. on behalf of Prof. PK Surendran Memorial Education Foundation. This is an open access article under the CC BY license (<http://creativecommons.org/licenses/by/4.0/>).



Fig. 1. Attitude of the patient at the time of presentation with Pseudo-flexion of hip and knee.

2.2. Diagnostic assessment

All routine blood investigations were found to be normal. Inflammatory markers including Erythrocyte Sedimentation Rate (ESR) and C-Reactive Protein (CRP) were within normal limits. Radiographs of the spine showed loss of lumbar lordosis. No other pathology was detectable on the radiograph. A radiograph of the pelvis was normal. Magnetic Resonance Imaging (MRI) revealed lumbar disc herniation of the L5-S1 disc as shown in Fig. 2. A posterior annulus tear was also noted at the same level. Screening of the rest of the spine showed no other abnormality. A radiograph of the pelvis was normal.

2.3. Differential diagnosis

The acute onset of pain and preceding history of lifting heavy suggested a traumatic aetiology. The presence of bladder symptoms, sensory loss and absent ankle jerk suggested possible nerve impingement, corresponding to the S1 nerve root being compressed. The MRI findings

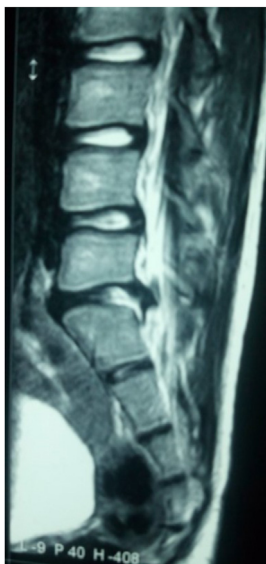

Fig. 2. MRI showing lumbar disc herniation and annulus fibrosis tear at the L5-S1 level.

were classical of lumbar disc herniation at the L5-S1 level. Yet screening of the remaining portion of the spine was warranted, as it was important to rule out the presence of any congenital or development spinal anomalies, other deformities.⁵ Absence of fever, normal total count, ESR and CRP helped rule out an infective cause. That, along with the absence of any vertebral body involvement and absence of disc degeneration, all but ruled out any tuberculous aetiology. Though the pseudo flexion deformity of the hip and knee were in all likelihood a result of hamstring tightness due to S1 nerve impingement, local pathology at the hip and knee still needed to be ruled out. Radiographs confirmed the absence of any local hip or knee pathology. Another important condition to rule out was the presence of any associated apophyseal fractures, which have often been reported to occur simultaneously with paediatric LDH.⁶ No apophyseal fractures were noted in the MRI in this case.

2.4. Therapeutic intervention

The child was given a trial of conservative management with analgesics and muscle relaxants for 2 weeks. However, there was no significant improvement in symptoms. Considering the inadequate response to conservative measures and the presence of bladder symptoms, early

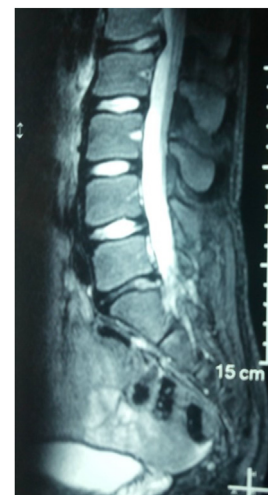

Fig. 3. MRI one year post interlaminar discectomy, showing no disc herniation at the L5-S1 level.

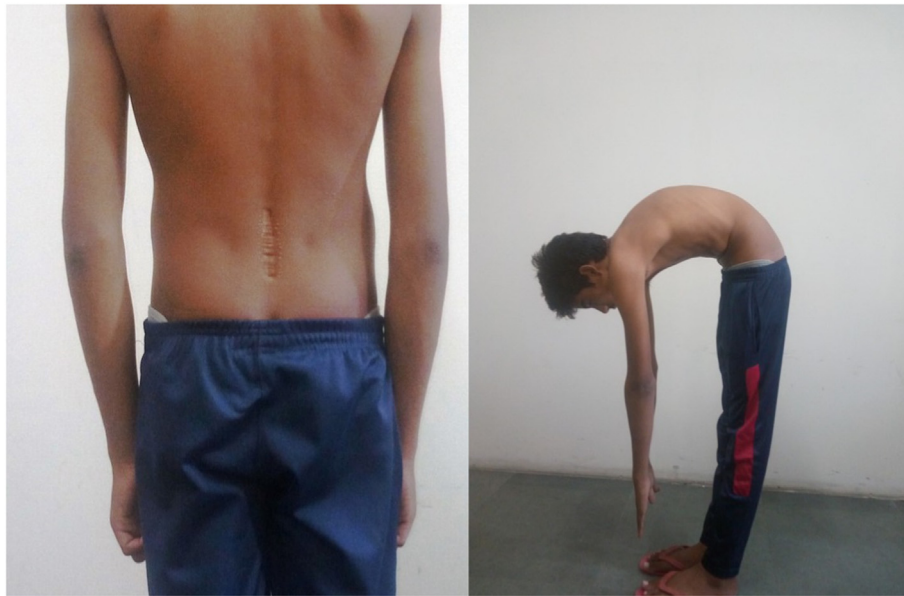

Fig. 4. Child at one-year postoperative follow-up, showing good functional outcome with normal extension and flexion of the spine.

operative treatment was recommended. We performed an interlaminar discectomy at the L5-S1 level on the right side. The offending herniated disc was excised. The patient was mobilised in the immediate post-operative period.

2.5. Follow-up and outcomes

The child had significant relief of pain in the immediate post-operative period. The pseudo flexion deformity of hip and knee, and bladders symptoms were absent postoperatively. He returned to his routine activities within two weeks of surgery. He successfully returned to sports activities six months following surgery. MRI performed one-year post-surgery showed no disc herniation at L5-S1 or any other levels as shown in Fig. 3. He had an excellent functional outcome as shown in Fig. 4, with his visual analogue score for pain decreasing from 8 points pre-operatively to one point post-operatively at one year follow up. Similarly, the Short-form 36 health survey score (SF-36) improved from 35 pre-operatively to 80 at one year follow up. The child was followed up for two years and was found to have no recurrence of symptoms.

3. Discussion

Paediatric LDH is a rare entity. Though the basic pathogenesis is similar to adult LDH, paediatric LDH is unique in various aspects. Apart from being much less common, a larger proportion of paediatric LDH occurs as a result of trauma.⁷ Apart from risk factors common to adult LDH like high body mass index, additional risk factors for paediatric LDH have been identified as cystic fibrosis, extensive athletic activity, facet joint asymmetries and lumbosacral transition vertebrae.⁸ The most common levels involved in descending order are L4-L5, L3-L4 and L5-S1.⁴ There, being only limited literature available on paediatric LDH, reports of LDH involving L5-S1 levels specifically is only limited to a few cases reports. Among these case reports as well, we were unable to come across any case presenting with pseudo flexion deformity of the hip and knee. While this presentation, did not necessarily change the surgical treatment chosen, it did warrant detailed evaluation of the hip and knee to rule out any local pathology. It also became a factor in limiting the duration of conservative management as the posture was debilitating and functionally restrictive. Complete resolution of this functional impairment was an important marker of the success of surgical treatment and was a priority for the child and his parents.

It has been reported by several authors that paediatric LDH patients responded less favourably to conservative treatment as compared with adults.^{9,10} There are several possible reasons for this. Well-hydrated discs in adolescents do not get resorbed like a dehydrated and degenerated adult disc. Lumbar posterior ring apophysis fractures often accompany paediatric LDH. Such fractures do not tend to heal spontaneously and often require surgical measures.^{4,6} Trauma preceding LDH is more common among children, and the annulus fibrosis could be severely damaged due to such trauma. Lastly, children and adolescents tend to be more active and less compliant for bed rest than adults. Despite this, conservative management with bed rest and analgesics remain the first line of management that should be attempted before the exploration of surgical options.¹¹ Epidural steroid injections have also shown favourable results, albeit with limited available data.¹²

Indications for surgical intervention are the same both for adults and adolescents, including the neurological deficit, failure of conservative treatment and frequent recurrent attacks.¹⁰ The most commonly performed surgical procedures are microdiscectomy and minimally invasive techniques: percutaneous endoscopic and tubular approaches to discectomy.⁸ Surgical treatment for paediatric LDH is associated with the excellent short-term outcome regardless of which surgical modality is chosen.^{4,5,9} Although the outcome begins to deteriorate in the mid-term follow-up,¹³ remains good in the long run. Spinal fusion is not recommended for children and adolescents with only a few exceptions.⁹

It is crucial to keep disc herniation as a differential diagnosis in children presenting with back pain. Pseudo flexion deformity of hip and knee could be an indicator of S1 nerve root compression. Paediatric LDH responds poorly to conservative management, but a good functional outcome can be achieved with prompt surgical management when indicated.

Informed consent

An informed consent was obtained from the parents of the child for this publication.

Declaration of patient consent form

Patient's parents declare no conflict of interest in publishing the case report for academic purposes.

Financial support and sponsorship

Nil.

Declaration of competing interest

Nil.

Acknowledgements

Nil.

References

1. Luukkonen M, Partanen K, Vapalahti M. Lumbar disc herniations in children: a long-term clinical and magnetic resonance imaging follow-up study. *Br J Neurosurg.* 1997; 11(4):280–285. <https://doi.org/10.1080/02688699746041>.
2. Lavelle WF, Bianco A, Mason R, Betz RR, Albanese SA. Pediatric disk herniation. *J Am Acad Orthop Surg.* 2011;19(11):649–656. <https://doi.org/10.5435/00124635-201111000-00001>.
3. Cahill J, Frost G, Solanki GA. Paediatric lumbar disc herniation in the very young: a case-based update. *Childs Nerv Syst ChNS Off J Int Soc Pediatr Neurosurg.* 2011;27(5): 687–691. <https://doi.org/10.1007/s00381-010-1369-6>.
4. Sarma P, Thirupathi RT, Srinivas D, Somanna S. Adolescent prolapsed lumbar intervertebral disc: management strategies and outcome. *J Pediatr Neurosci.* 2016; 11(1):20–24. <https://doi.org/10.4103/1817-1745.181259>.
5. Smorgick Y, Floman Y, Millgram MA, Anekstein Y, Pekarsky I, Mirovsky Y. Mid- to long-term outcome of disc excision in adolescent disc herniation. *Spine J Off J North Am Spine Soc.* 2006;6(4):380–384. <https://doi.org/10.1016/j.spinee.2005.10.015>.
6. Wu X, Ma W, Du H, Gurung K. A review of current treatment of lumbar posterior ring apophysis fracture with lumbar disc herniation. *Eur Spine J.* 2013;22(3):475–488. <https://doi.org/10.1007/s00586-012-2580-9>.
7. Shimony N, Louie C, Barrow D, et al. Adolescent disc disease: risk factors and treatment success-related factors. *World Neurosurg.* 2021;148:e314–e320. <https://doi.org/10.1016/j.wneu.2020.12.126>.
8. Raghu ALB, Wiggins A, Kandasamy J. Surgical management of lumbar disc herniation in children and adolescents. *Clin Neurol Neurosurg.* 2019;185, 105486. <https://doi.org/10.1016/j.clineuro.2019.105486>.
9. Dang L, Liu Z. A review of current treatment for lumbar disc herniation in children and adolescents. *Eur Spine J Off Publ Eur Spine Soc Eur Spinal Deform Soc Eur Sect Cerv Spine Res Soc.* 2010;19(2):205–214. <https://doi.org/10.1007/s00586-009-1202-7>.
10. Bulos S. Herniated intervertebral lumbar disc in the teenager. *J Bone Joint Surg Br.* 1973;55(2):273–278.
11. Ozgen S, Konya D, Toktas OZ, Dagainar A, Ozek MM. Lumbar disc herniation in adolescence. *Pediatr Neurosurg.* 2007;43(2):77–81. <https://doi.org/10.1159/000098377>.
12. Slotkin JR, Mislow JMK, Day AL, Proctor MR. Pediatric disk disease. *Neurosurg Clin N Am.* 2007;18(4):659–667. <https://doi.org/10.1016/j.nec.2007.08.001>.
13. Parisini P, Di Silvestre M, Greggi T, Miglietta A, Paderni S. Lumbar disc excision in children and adolescents. *Spine.* 2001;26(18):1997–2000. <https://doi.org/10.1097/00007632-200109150-00011>.