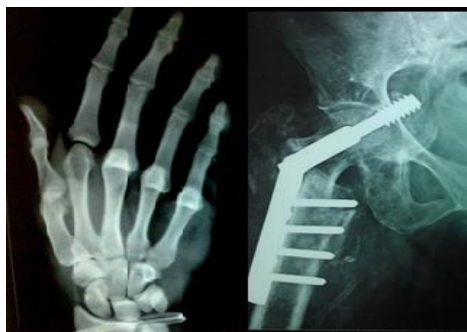

International Journal of Orthopaedics Sciences

ISSN: 2395-1958
IJOS 2018; 4(3): 82-86
© 2018 IJOS
www.orthopaper.com
Received: 17-05-2018
Accepted: 18-06-2018

Dr. AN Sarath Babu
Senior Assistant Professor,
Institute of Orthopaedics and
Traumatology, Rajiv Gandhi
Government General Hospital,
Chennai, Tamil Nadu, India

Dr. Naveen Kumar
Consultant Orthopaedic Surgeon,
Chennai, Tamil Nadu, India

Dr. M Sathish
Junior Resident MS Ortho Post
graduate, Institute of
Orthopaedics and Traumatology,
Rajiv Gandhi Government
General Hospital, Chennai,
Tamil Nadu, India

Dr. N Sukumar
Junior Resident, MS Ortho Post
graduate, Institute of
Orthopaedics and Traumatology,
Rajiv Gandhi Government
General Hospital, Chennai,
Tamil Nadu, India

Correspondence

Dr. M Sathish
Junior Resident MS Ortho Post
graduate, Institute of
Orthopaedics and Traumatology,
Rajiv Gandhi Government
General Hospital, Chennai,
Tamil Nadu, India

Outcome analysis of management of recurrent shoulder dislocation by Latarjet procedure

Dr. AN Sarath Babu, Dr. Naveen Kumar, Dr. M Sathish and Dr. N Sukumar

DOI: <https://doi.org/10.22271/ortho.2018.v4.i3b.17>

Abstract

Introduction: With the extreme range of movements, the shoulder joint is prone for dislocations. This could be due to traumatic or atraumatic, though the majority are atraumatic. With each subsequent episode of dislocation, humeral head, the glenoid, capsule, labrum and the ligaments undergoes progressive degeneration which further worsens the situation. Selecting an optimal and efficient surgical procedure for patients with anterior glenohumeral instability and associated glenoid bone loss is a complex problem. Among the coracoid transfer procedures, open Latarjet procedure offers good clinical outcomes even with engaging Hill sach's along with glenoid bone loss. The purpose is to study the clinical outcome of Open Latarjet procedure in anterior glenohumeral instability and even with Hill Sach's lesion.

Materials & Methods: Twenty patients with recurrent dislocation were performed Open Latarjet Procedure. All patients were screened by arthroscopy through standard portals of the shoulder before open procedure. Patients were followed up for mean period of 22 months. The functional outcome was measured with Walch Duplay and Visual analog scores.

Results: All twenty patients had solid bone union. 90% of the patients had excellent to good outcomes. 10% of these patients had developed Grade 1 Humeral Arthropathy and this is due to improper instrument selection. One patient had transient axillary nerve weakness which recovered fully within 3 months period. During the first 10 months, there is significant loss of external rotation. But during 18 to 20 months period, there is significant improvement in the range of external rotation. None of the patient developed recurrent dislocation or positive apprehension. All patients have resorted back to routine work after 6 months period.

Conclusion: Open Latarjet procedure offers a good surgical method of management of recurrent anterior shoulder dislocation with significant bone loss and our study showed good functional outcome as measured by Walch Duplay and VAS scores.

Keywords: Glenohumeral instability, Latarjet procedure, Hill sach lesion

Introduction

The shoulder joint allows extreme range of motion in the human body. This wide range of motion has developed through the interplay of bony and soft tissue anatomy providing for increased kinematics and thus resulting in increased chances of instability. Shoulder dislocation is the most common form of joint dislocation (31%). With subsequent episodes of dislocation, humeral head, the glenoid, capsule, ligaments and the labrum undergoes progressive alterations [1]. Anatomical repairs aim at attaching the torn glenoid labrum to its original position thereby achieving the proper tension in the shoulder complex. e.g: Bankart repair – Montgomery & Jobe, Inferior capsular shift procedure- Neer. When there is substantial loss of Glenoid width isolated soft tissue repairs have exhibited failure rates as high as 57% to 67% [3].

Balg & Boileau *et al.* [4] in their study found that the outcome of Bankart repair were affected by Instability Severity Index Score with recurrence rate of 5% for patients with score 3 or less, 10% for patients with score 6 or less and 70% for patients with score more than six and advised open glenoid bone graft procedure for score more than 6. Burkhart & Debeer *et al.*, [2] in 190 patients with arthroscopic procedures found a recurrence rate of 6.5% to 89% in patients involved in contact sports, glenoid defect more than 25% or an engaging hill sach

lesion. Voos *et al.* in their study had a recurrence rate of 37.5% in patients with glenoid defect more than 25% and a larger hill sach lesion, who had undergone arthroscopic repair. The Non-anatomical repair aims at stabilizing the shoulder girdle by compensating for the capsular and labral tears with or without bony injury, with bony/soft tissue structures which prevents the excessive anterior displacement of humeral head thereby stabilizing the joint. e.g.: Bristow and Latarjet, Magnuson-Stack - De- Palma and Putti-Platt.

Coracoid transfer procedures^[5], have shown promising results because of the additive dynamic stabilizing sling effect produced by the repositioned conjoint tendon. The purpose of this study is to analyse the stabilization effects of Latarjet Procedure in anterior glenohumeral instability and analyse outcomes.

Materials and methods

This is a retrospective and prospective study conducted at our Institute from July 2014 to June 2018. The patients were included in the study based on the following Inclusion/Exclusion criteria after getting consent of the patient.

Inclusion Criteria

1. Recurrent Anterior shoulder dislocation
2. Bankart lesion (25-40%)
3. Large Hill sach lesion
4. ISIS score 6 or more.

Exclusion Criteria

1. Multidirectional instability
2. Fracture dislocations
3. Congenital ligament laxity
4. Neuromuscular disorder
5. Bankart lesion (< 25% or >40% loss)
6. Hill sach lesion (>40% loss)
7. ISIS score less than 6.

Patients with Recurrent anterior shoulder dislocation are selected in for clinical study as per above criteria. A detailed history regarding name, age, sex, date of first episode of dislocation, age at the time of first episode, mechanism of injury, number of dislocations, residential address, and occupational status was recorded. Patients are subjected to routine blood investigations like complete haemogram, renal function tests. X rays of shoulder True anteroposterior view and Stryker notch view taken to demonstrate Glenoid defect and Hill sach lesions. CT scan is the investigation of choice as it assesses the extent and the size of the bony lesions, which were under appreciated previously in x-rays. MRI is useful to evaluate labral tears, SLAP tears, HAGL & ALPSA lesions. Patients were selected after appropriate radiographs, CT and MRI scans and taken up for surgery. We used shoulder instability severity index and Glenoid bone loss percentage to

assign our patients for surgery.

All 20 cases were done under general anesthesia with patient in beach chair position. We used Delto pectoral approach for all cases. Expose the conjoined tendon. In Latarjet technique, the coracoid is sectioned along with the Coracoacromial ligament and osteotomized at its base. Insert the bone block along with the Coracoacromial ligament through the split subscapularis and place it flush to antero-inferior margin of glenoid, keeping the inferior surface of coracoid in contact, repair the Coracoacromial ligament with Capsule.

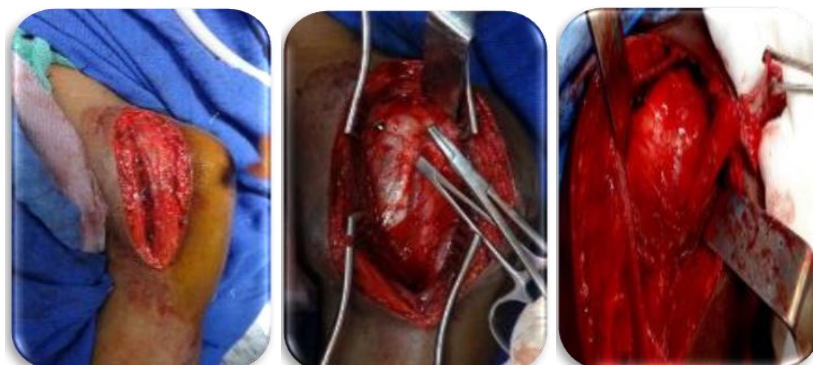
Postoperatively patients were immobilized in a Shoulder immobilizer, with the arm against the body, drain removal on 2nd postoperative day, intravenous antibiotics for 5 days, from Day 1 Ice and Ball squeeze therapy, from Day 1 to 2 weeks immobilization in sling or shoulder immobilizer, 2 to 6 weeks start active assisted Forward flexion, Codman pendulum exercises, abduction range of motion exercises, 6 to 8 weeks start external rotation exercises, from 8 weeks start Isometric shoulder strengthening exercises, can return to activity after 12 weeks and can indulge Non-contact sports after 3months.

Periodic radiographs were requested to evaluate the union, screw position and arthritic changes. Post-operative arthropathy was measured using Samilson Prieto grading. CT scan has been taken to find out union. None had been lost to follow-up. The functional outcome was measured using Walch Duplay score & Visual analog score. Minimum follow up period – 6 months. Maximum follow up period – 5 yrs. The mean follow up was 22 months.

In our series, 3 cases (16%) were in the age group of < 20 yrs, 15 cases (70%) were in 20-35 yrs, 2 cases (13%) were in > 35yrs. Recurrence rate is inversely proportional to the age at the time of initial dislocation and the severity of the injury. Majority of patients in our study fall in the age group between 20 to 35 yrs with mean age of 28.37 years. In our series twenty-one (70%) cases presented more than one year after first dislocation, with mean duration of 2.30 years. In our series sports injuries account for 17 cases (56.7%), RTA seven cases (23.3%) and fall six cases (20%). Mean duration of surgery for Latarjet = 158 mins. Mean glenoid loss = 26.28%.

Results

All twenty patients had solid bone union. 90% of the patients had excellent to good outcomes. 10% of these patients had developed Grade 1 Humeral Arthropathy. One patient had transient axillary nerve weakness which recovered fully within 3 months period. During the first 10 months, there is significant loss of external rotation. But during 18 to 20 months period, there is significant improvement in the range of external rotation. None of the patient developed recurrent dislocation or positive apprehension. All patients have resorted back to routine work after 6 months period.



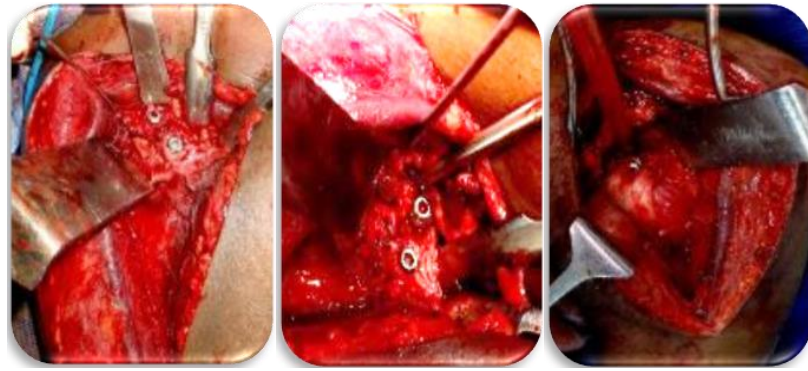


Fig 1: Showing the key surgical steps in the management of recurrent anterior shoulder instability by Latarjet procedure

Discussion

The outcome following Latarjet surgery for recurrent anterior shoulder dislocation depends on the pre evaluation, number of previous dislocations, age, sex, associated injuries and finally the experience of the operating surgeon [6]. Mean age of patients was 28.37 years in our study with majority (70%) belonging to the age group of 20 – 35 years. All the affected patients were male (100%) which is well evidenced by most of the Studies [7]. In 65% of the cases, the dominant side is involved, which in our study was right shoulder [8] (13

patients). Mean number of episodes of recurrent dislocation prior to surgery were 15.5 times (range 15 -60). Mean duration of illness 2.3 years. And the most common mechanism of violence was due to Recreational/sports injury [9] (56.6%), followed by motor vehicle accident (23.3%) and unspecified falls (20%). Mean glenoid bone loss in our series is 26.28. Hill sachs lesion is seen in majority (70%) of case. Patients in our series had no recurrence, which was far better when compared to other similar studies. Spoor *et al* had a recurrence rate of 5% [10].

Table 1: showing the master chart of outcome of the study in correlation with the outcome scores

Variable		Excellent	Good	Fair	Total
Age	<20yrs	2	1	--	3
	20-35yrs	13	1	1	15
	>35yrs	1	--	1	2
Duration of illness	<1yr	8	3	--	11
	>1yr	7	2	--	9
Side	Right	11	4		15
	Left	2	1	2	5
Duration of surgery	<2yrs	10	5		15
	>2yrs	1	2	2	5
Mechanism of injury	Sports	12	1		13
	TTA	1	--	1	2
	Fall	3	1	1	5
No. of dislocations	<20	16	1	1	18
	>20	--	1	1	2
Follow up	<1yr	--	5	1	6
	>1yr	12	1	1	14
Post op apprehension		--	--	--	--
Total outcome		16	2	2	20

CT scan was done postoperatively and all 20 patients had bony union (100%) and screw positioning was assessed. There is no lateral overhang or too medial positioning of coracoid in our series. Outcome in our series is based on the Walch Duplay score and is found to be excellent in 40%, Good outcome is seen in 46.7%, Fair outcome of 13.3%.

Hovelius *et al.* [13] in his series of 118 shoulders with 15 year follow up, had good/excellent outcome in 86 to 98%. 16% incidence of screw migration and 28% incidence of fibrous union, loss of external rotation by 10 degrees and 36% of malposition above equator.

Table 2: Showing the comparison of the followup period and the outcome of our study with other similar studies on Latarjet procedure.

S. No	Study	Excellent to Good outcome	Follow up(months)
1	Singer <i>et al.</i> [11]	93%	246
2	Banas <i>et al.</i> [12]	85%	103
3	Hovelius <i>et al.</i> [13]	86%	182
4	Pap <i>et al.</i> [14]	84%	31
5	Matthes <i>et al.</i> [15]	83%	38
6	Our study	90%	22

Schroder *et al* in 52 cases found instability in 15.4% with 26.4-year mean follow up & had Good outcome in 70% cases. Yamashita *et al.* [16] in 126 shoulders reported 90% good

results with mean follow up of 41 months. Farzad *et al.* [17] in study of 35 cases had 54 % of dominant extremity involvement with excellent results in 31% and good in 69%

cases Matthes *et al* in his series of 29 patients had a mean age of 26 years. Mean number of dislocations being eight. Had an excellent result in 59% good results in 24% and fair in 10%, poor in 7 %. Recurrence rate following surgery is 0% in our series. Griesser *et al* in a meta-analysis of 1904 cases of Bristow-Latarjet found a recurrence rate of 2.9 to 5.8%

following Bristow-Latarjet techniques. Balg & Boileu *et al.* [18] in their series had a recurrence rate of 70% in cases of arthroscopic Bankart repair with ISIS score more than six, they recommend Bristow-Latarjet procedures in such cases. 20% of Latarjet cases developed Grade 1 Humeral Arthropathy

Table 3: Showing the comparison of improvement of the outcome scores on follow up post latarjet procedure.

Study	Walch duplay score				
	Preop	3m post op	6m post op	12m post op	22 m post op
Edouard <i>et al.</i> [19]	55.3	63.3	84.0	86.1	90.8
Our study	29.33	52.0	72.67	85.00	95.00

Joshua giles *et al.* [20] al in their cadaveric study comparing Bristow and Latarjet techniques found no difference in joint stiffness in 0% glenoid bone loss however greater joint stiffness with Latarjet procedure for 15 to 30% glenoid bone loss. Latarjet restored the joint stiffness that was measured in intact state in 91% cases. They had dislocation rate 0 % dislocations with Latarjet. In patients with engaging Hill sach lesions, Latarjet gives better results than Modified Bristow. Once the follow up is more than a year, the functional outcome significantly improves showing similar results with both the techniques. Post operatively three (20%) Modified Bristow cases continued to have positive apprehension test which is significantly higher than Latarjet (0%). Edouard *et al.* [19] in their series of twenty patients had mean walch duplay score of (55.3) preop, 3 month post op, (84.0) 6 month post op and (90.8) 21 month post op (Table-3).

In our study the following three factors were taken into account to obtain good results postoperatively;

1. Screw should be placed ideally below the equator anteroinferior aspect of glenoid and it should be within 5-10 mm from the rim (joint space) of glenoid after freshening the ends.
2. Adequate postoperative immobilization - period of 2 weeks to promote healing.
3. 4mm cannulated cancellous screws of sizes 35 to 40mm were used in our study to get Bicortical purchase

Conclusion

Our study results provide evidence that Latarjet procedure effectively restore joint stability in anterior Glenohumeral instability patients with Glenoid deficiency. Selection of the patients with proper history, physical examination, radiographs, computed tomograms and MRI is mandatory, with significant importance to the size and site of the bone defect. Surgeons should be aware that these procedures are technically demanding and we recommend experienced orthopaedic surgeons familiar with normal and abnormal anatomy of shoulder. Therefore, in terms of efficacy, Latarjet will be a preferable procedure in coracoid transfer surgeries for Anterior Glenohumeral instability with significant Glenoid bone loss.

References

1. Robinson CM, Howes J. Functional outcome & risk of recurrent instability after primary traumatic anterior shoulder dislocation in young patients. JBJS. 2006; 88(11):883-892.
2. Burkhart SS, De beer. Traumatic glenohumeral defects & their relationship to failure of arthroscopic Bankart repair. Arthroscopy. 2000; 16(7):677-694.
3. Lo IK, Parten PM, Burkhart SS. The Inverted peer glenoid, an indicator of significant bone loss.

Arthroscopy. 2000; 20(2):169-174.

4. Balg F, Boileau P. The instability severity index score. A simple pre-operative score to select patients for arthroscopic or open shoulder stabilization. JBJS. 2007; 89(11):1470-1477.
5. Miniaci A, Gish W. Management of anterior glenohumeral instability associated with large Hill-Sach lesion. Tech shoulder Elbow surg. 2004; 5(3):170-175.
6. Piasecki DP, Verma *et al.* Glenoid bone deficiency in recurrent anterior shoulder instability; Diagnosis and Management. J Am Acad Ortho Surg. 2009; 17(8):482-493.
7. Joshua Giles W, Ryan Degen M. Bristow & Latarjet-why these procedures should not be considered synonymous. JBJS. 2014; 96:1340-8.
8. Montgomery WH, Jobe FW. Functional outcomes in athletes after modified anterior capsulolabral reconstruction. Am J Sports Med. 1994; 22:352.
9. Samilson RL, Prieto V. Dislocation arthropathy of the shoulder. J Bone Joint Surg Am. 1983; 65:456-60.
10. Edouard. Relationship between strength and fuctional index scores after shoulder stabilization surgeries. Annals of Physical & Rehabilitation medicine. 2010; 53:499-510.
11. Singer GC, Kirkland PM. Coracoid transposition for recurrent shoulder dislocation. A 20 year follow up study; JBJS. 1995; 77(1):73-76.
12. Banas RL, Prieto V. Dislocation arthropathy of the shoulder. / Bone and Joint Surg. 1983; 65-A:456-460.
13. Hovelius L, Saeboe M. Neer award 2008, arthropathy after primary anterior shoulder dislocation-223 shoulders prospectively followed up for twenty-five years, | Journal of Shoulder and Elbow Surgery. 2009; 18(3):339-347.
14. Pap G, Machner A, Merk H. Treatment of recurrent traumatic shoulder dislocations with coracoid transfer-Latarjet-Bristow operation. 1997; 122:321-6.
15. Matthes G, Horvath V, Seifert J. Oldie but goldie: Bristow-Latarjet procedure for anterior shoulder instability. Journal of Orthopaedic Surgery. 2007; 15(1):14-18.
16. Yamashita N, Muraki T, An KN, Sperling JW, Cofield RH, Itoi E *et al.* The stabilizing mechanism of the Latarjet procedure: a cadaveric study. J Bone Joint Surg Am. 2013; 7(95):1390-7.
17. Farzad RJ, Angelo RL. Glenohumeral osteoarthritis. A late complication of the Putti-Platt repair. J Bone and Joint Surg. 1990; 72-A:1193-1197.
18. Boileau P, Mercier N, Roussanne Y, Th'elu CH, Old J. Arthroscopic Bankart-Bristow-Latarjet procedure: the development and early results of a safe and reproducible technique, | Arthroscopy. 2010; 26:1434-1450.
19. Edouard P, Beguin L, Fayolle-Minon I, Degache F,

Farizon F, Calmels P. Relationship between strength and functional indexes (Rowe and Walch-Duplay scores) after shoulder surgical stabilization by the Latarjet technique, | *Annals of Physical and Rehabilitation Medicine*. 2010; 53(8):499-510.

20. Joshua Giles W, Ryan Degen M. Bristow & Latarjet-why these procedures should not be considered synonymous. *JBJS*. 2014; 96:1348-9.