i An update to this article is included at the end

Journal of Clinical Orthopaedics and Trauma 44 (2023) 102257

Contents lists available at ScienceDirect

Journal of Clinical Orthopaedics and Trauma

journal homepage: www.elsevier.com/locate/jcot

Mycobacterium Tuberculosis infection of the wrist joint: A current concepts review

Mohit Singh [a], Madhan Jeyaraman [b], Naveen Jeyaraman [b], Tarun Jayakumar [c], Karthikeyan. P. Iyengar [d], Vijay Kumar Jain [a, *]

[a] Department of Orthopaedics, Atal Bihari Vajpayee Institute of Medical Sciences, Dr Ram Manohar Lohia Hospital, New Delhi, 110001, India
[b] Department of Orthopaedics, ACS Medical College and Hospital, Dr MGR Educational and Research Institute, Chennai, 600056, Tamil Nadu, India
[c] Department of Orthopaedics, KIMS-Sunshine Hospital, Hyderabad, 500003, Telangana, India
[d] Trauma and Orthopaedic Surgeon, Southport and Ormskirk NHS Trust, Southport, PR8 6PN, UK

ARTICLE INFO

Article history:
Received 9 June 2023
Received in revised form
9 July 2023
Accepted 25 September 2023
Available online 28 September 2023

Keywords:
Mycobacterium tuberculosis
Tuberculosis
Osteoarticular
Wrist
Diagnosis
Treatment

ABSTRACT

Background: Osteoarticular Tuberculosis (TB) of wrist joint is a rare, often misdiagnosed form of site affected by *Mycobacterium Tuberculosis* infection that can lead to severe disability and morbidity. This review aims to summarize the current literature on the diagnosis and management of *Mycobacterium Tuberculosis* infection of the wrist joint.

Materials and methods: A comprehensive search strategy using the PEO (Population, Exposure, Outcome) framework was conducted on PubMed, Google Scholar, and Web of Science databases from 1967 to 2022, excluding single case reports and correspondence articles. The keywords used for the search included '*Mycobacterium tuberculosis*' 'osteoarticular' and 'wrist'. Clinical presentation, demographic details, complementary investigations undertaken, trends, and complications of different management interventions were recorded to generate this review.

Results: Osteoarticular Tuberculosis (TB) of the wrist joint accounts for fewer than 1% of all skeletal TB cases across a spectrum of age ranges. Magnetic Resonance Imaging (MRI) represents an excellent modality to reveal the extent of the disease at an early stage of the condition. Synovial fluid analysis has been recommended for microbiological diagnosis. Treatment options include anti-tubercular therapy (ATT), incision and drainage, debridement, synovectomy, and arthrodesis.

Conclusion: Early diagnosis and treatment of wrist tuberculosis is crucial for achieving good functional outcomes in patients with this uncommon condition. Polymerase Chain Reaction (PCR) and GeneXpert technology for the detection of ***Mycobacterium tuberculosis*** (MTB) have improved diagnostic accuracy in detecting MTB DNA and rifampicin resistance. Anti-Tubercular Therapy (ATT) regime remains a foundation pillar in the overall management of these patients with focused surgical interventions leading to improved clinical outcomes.

© 2023 Delhi Orthopedic Association. All rights reserved.

1. Introduction

Mycobacterium tuberculosis (MTB) infection still remains a major world-wide public health concern with increased incidence, prevalence in low-medium income countries and developing countries. Almost one-third of cases of extra-pulmonary TB is associated with musculoskeletal (MSK) TB. Wrist joint tuberculosis (WJ-TB) is a rare complication of MSK-TB and account for less than 1% of all osteoarticular TB.[1]

The wrist is an ellipsoid-type synovial joint consisting of bones, ligaments, triangular fibro-cartilage complex, and surrounding flexor and extensor muscles. Grip, grasp, twist, hook, pinch, prehension, and perception are some of the essential functions of the wrist of the hand.

Consequently; delayed diagnosis of WJ-TB and untreated cases may impair wrist function for required for activities of daily living (ADL) and may lead to a significant morbidity. Early diagnosis is challenging due to its insidious presentation and spectrum of presentations. Hence definitive diagnosis may often take 16–19 months.[1] WJ-TB is predominantly caused by hematogenous spread

* Corresponding author.
E-mail address: drvijayortho@gmail.com (V.K. Jain).

https://doi.org/10.1016/j.jcot.2023.102257
0976-5662/© 2023 Delhi Orthopedic Association. All rights reserved.

from a pulmonary foci, although it can also be triggered by iatrogenic injection, local dissemination, or lymphatic spread in some adults.[2] Delayed treatment leads to osteo-cartilage destruction and joint space narrowing of the Wrist joint. A detailed history, focussed clinical examination, complementary radiological investigations, and guided biopsy can help in early diagnosis and prevent complications such as median nerve compression, wrist deformity, tendon rupture, etc.

Multidrug anti tubercular therapy (ATT) remains the mainstay of treatment in all WJ-TB patients; however, in some circumstances, surgical intervention is also essential to prevent further deformity and restore wrist function.

Currently, only a handful of case series have been published on the topic of WJ-TB with the majority of studies being case reports. In this review, we attempted to collect all published information from data available on PubMed, Google Scholar, and Web of Science databases from 1967 to 2022. (Table 1). We excluded single case reports and correspondence articles. The keywords used for the search included '*Mycobacterium tuberculosis*' 'osteoarticular' and 'wrist'. Clinical presentation, demographic details, complementary investigations undertaken, trends, and complications of different management interventions were recorded to generate this review.

A comprehensive review of a large number of WJ-TB cases has yet to be published and furthermore, no conventional treatment exists for WJ-TB, and its efficiency is unknown.

This review aims to summarize the current literature on the diagnosis and trends in management of *Mycobacterium Tuberculosis* infection of the wrist joint.

2. Site and incidence of TB wrist

Extrapulmonary tuberculosis (EPTB) accounts for 15−20% of all tuberculosis cases in immunocompetent patients and more than 50% of cases in immunocompromised patients such including HIV-positive individuals. Recently due to the rise in the use of biological, and chemotherapeutic agents, there is a sharp rise in the number of extrapulmonary tuberculosis cases. Bone and joints account for about 10% of all EPTB. Hand and wrist tuberculosis is a rare form of tuberculosis when compared to the load-bearing joints such as knee and hip, and accounts for less than 1% of all skeletal TB cases. The incidence of TB wrist is low, accounting for only 1.1% of cases. In a series by Kotwal et al. only 6.2% of cases had wrist TB.[3]

3. Route of infection

TB wrist is associated with active or past history of pulmonary tuberculosis with about one out of 8 (12.5%) cases having a positive history of active pulmonary TB.[4,5] The infection spread from the metaphysis to the joint after invading the epiphysis, causing subcortical bone destruction and cartilage damage. Direct inoculation of tuberculosis is rare and may occur following iatrogenic introduction following surgery or trauma. In about 28% wrist TB cases history of trauma has been recorded.[4] Wrist overuse has also been implicated as a cause of wrist TB.[6]

4. Clinical presentation

4.1. Manifestation

The patient may or may not present with characteristic systemic symptoms such as loss of weight, loss of appetite, night sweats, fever, and night cry.[7] Some of these patients had been in contact with TB patients or had tuberculosis elsewhere in their bodies. Tuberculosis infection of the wrist can affect any tissue (tendon, muscle, bone) and usually manifests with unilateral predominance. WJ-TB can be divided into three categories: tuberculous tenosynovitis, compound ganglion, and tuberculous osteomyelitis, which are usually in overlapping stages at the time of presentation.[8] Yushan et al. in their series on WJ-TB reported that 32% of patients had bone involvement and 68% had involvement largely in soft tissues such as flexor or extensor tenosynovitis and wrist synovitis.[4] Volar tenosynovitis is more common than dorsal tenosynovitis.[9] Ganglion formation along the volar carpal ligament which appears as soft tissue swelling may also be a symptom of TB tenosynovitis.[10]

4.2. Symptoms

Initial symptoms in patients with TB wrist are mild. Chronic swelling is the universal symptom among patients with WJ-TB (Figs. 1 and 2). However, sometimes it may also be associated with dull-aching pain.[8] Pain is usually mild to moderate and occurs with wrist movements. Patients may present with symptoms of carpal tunnel syndrome if there is a compression of the median nerve due to an abscess or destruction of carpal bones which may present as the initial manifestation of WJ-TB.[11–14] In a study by Kotwal et al. 15% of WJ-TB patients presented with soft-tissue involvement, and had features of carpal tunnel syndrome due to synovitis and flexor tenosynovitis.[3] In delayed cases, non-healing ulcers or multiple draining sinuses can develop if this infection persists for a longer time (Fig. 3). In late cases patients may present with Palmar-flexion deformity of wrist joint due to subluxed distal radioulnar joint and or wrist joint (Fig. 1). Apart from the aforementioned symptoms, para-articular muscular spasms, and joint stiffness are also documented symptoms. Secondary osteoarthritis with considerable painful wrist deformity and poor function may be the late manifestation of WJ-TB.[4,15]

4.3. Signs

Patients with WJ-TB mostly present in a later stage due to slow growing disease process. Common signs are localized tenderness, decreased range of wrist movements, signs of carpal tunnel syndrome and enlargement of supratrochlear and axillary lymph nodes. The presence of multiple sinuses fixed to the underlying tissues can also be seen. If the infection extends to the distal radioulnar joint, difficulty in supination and protonation may be seen. Further propagation of infection may cause subluxation and dislocation of joints and signs of instability can be demonstrated.

5. Investigations

Hematological investigations: Although tissue biopsy is the gold standard invasive method for the diagnosis of WJ-TB. A blood picture showing relative lymphocytosis, anaemia, leukocytosis, thrombocytosis, monocytosis, high Erythrocyte sedimentation rate (ESR) and C-reactive protein (CRP) values is often associated with the active stage of the tubercular disease. These markers are non-specific and they just point toward the diagnosis of infective or inflammatory pathology. CRP is shown to have 90% sensitivity and a 70% specificity.[9]

6. Radiological investigations

6.1. Plain radiography

Plain radiographs (X-rays) show features such as soft-tissue swelling with or without punctate calcification.[11] The initial radiographs may be normal showing only diffuse osteopenia, however, in later stages, joint destruction and narrowing can be seen.[16]

Table 1
Summary of clinical studies on Tuberculosis (TB) wrist in the English Literature.

Authors & Year of study	No. of cases	No. of wrist	Age Ranges & mean age (in years) and Sex	Bony involvement	Clinical Presentations	Investigation					Treatment	Outcome	Complications (Death, Recurrence, Others)	Remarks
						Culture	Histopathology	Tuberculin test	GeneXpert/ CBNAAT/ PCR	NCV				
Robins et al.[53] (1967)	95	39	20–60 Mean age NA	NA	Pain Swelling 39(100%) D.S. 7(17.9%) Stiffness	+ve	+ve	NA	NA	NA	13(33.3%) patients received antibiotics. Immobilization 39(100%) Excision/curettage 7(17.94%) Arthrodesis 8(20.5%)	Painless mobile 3(7.7%) Spontaneous fusion (ankylosis) 4(10.2%) Fibrous ankylosis 9(23.07%)	Ruptured Tendons + chronic D.S. 7(17.7%) Recurrence 5(12.8%)	EPTB (except wrist) 17(43.58%) Pul.TB 10(25.64%)
Brashear et al.[48] (1975)	10	10	22-70 (46)	Bony 7(70%) TS 3(30%)	Swelling 10(100%) Stiffness10 (100%) D.S. 6 (60%) CTS 1(10%) Pain	8 (80%)	5 (50%)	10 (100%)	NA	1 (10%)	H + PAS Streptomycin in peri-operative period x 6–18 month Splinting of joint Tenosynovectomy 3(30%) Arthrodesis 6(60%) Debridement 1(10%)	f/u 10 year ROM decrease in Tenosynovectomy cases(up to 10°)	Death 1(10%)	Pul. TB 7(70%)
Leung et al.[8] (1978)	11	4	38 to 93 (61) 2 M 2F	Wrist TS 4(100%) Bone name NA	Swelling 4(100%) Pain 2(50%) Numbness 3(75%) D.S. 2(50%)	4 (100%)	4 (100%)	NA	NA	NA	Radical synovectomy 4(100%) splinting of joint 4(100%) S 0.75 gm for 6 month PAS 10 gm and H 400 mg for one year	F/u up to 8 month Hand function & ROM (Bickel et al.) * Poor 2(50%) *fair 1(25%) *excellent 0%	Suicidal death 1(25%) Re-exploration 3(75%) Recurrence 0%	Miliary TB 1 (25%)
Benkeddache et al.[49] (1982)	27	8	16 to 54 Mean (NA)	8 wrist, Bone name NA	Pain Swelling Fistulae Stiffness constitutional symptom	+ve	7 (88.8%)	7 (85.2%)	NA	NA	HRZS x 2 month HRZ x 4 month Arthrodesis 2(25%) Splinting of joint 8(100%)	F/u of 1year ROM Painless mobile and decrease swelling was outcome	MDR 0%)	Pulmonary TB 1 (12.5%) Wrist x-ray Sequestrum 5(62.5%)
Bush et al.[43] (1984)	11	10	30–66 (50.18) M 8 F 3	9 patient 10 wrists (1 B/L)	Out of 9 patient Pain 4(44,4%) Swelling 9(100%) Stiffness 1(11.1%) CTS 2(22.2%)	9 (100%)	9 (100%)	NA	NA	2 (22%)	Antitubercular drug (No definitive duration protocol given) I&D 2(22.2%) CTD 2(22.2%) Synovectomy 9(100%) Aspiration then steroid injection 4(44.4%) Physiotherapy	Wrist apparent cure 8(88.8%) ROM NORMAL in 5(55.5%) Radiological healed 1(11.1%)	Wrist x-ray cystic lesion 2(22.2%) Failure with D.S. 2(22.2%)	Old Pul. Tb 1(11.1%) Active Pul. TB 1(11.1%) Tb hip 1(11.1%) Tb ankle 1(11.1%)
Visuthikosol et al.[9] (1996)	23	16	20 to 72 (50) M 8 F 6	14 patient 16 wrist (2 B/L) 11 soft tissue 2 carpal bone 3 both	Swelling 14(100%) Pain 14(100%) D.S. 2(14.29%) CTS 3(21.4%)	4 (28.6%)	14 (100%)	NA	NA	NA	Isolated wrist tb; H + PAS/E x 2 year and S x 3 month Tb wrist with Pulmonary HRE 6 month	F/u of 2 year Pain and swelling decrease in 14(100%) Improvement in ROM and power grip in 14(100%) but	Recurrence 0%	Pul. Tb 9(64.3%) CT-scan showed diffuse peritendinous

(*continued on next page*)

Table 1 (*continued*)

Authors & Year of study	No. of cases	No. of wrist	Age Ranges & mean age (in years) and Sex	Bony involvement	Clinical Presentations	Investigation					Treatment	Outcome	Complications (Death, Recurrence, Others)	Remarks
						Culture	Histopathology	Tuberculin test	GeneXpert/ CBNAAT/ PCR	NCV				
											H + PAS/E for 18 month S for 3 month Splint 1month physiotherapy	surgical treated group yield better results.		
Skoll et al.[54] (1999)	12	7	25 to 60 (40) M 4 F 3	7 wrist	Pain 1(14.3%) Swelling 2(28.6%) Sinus 3(42.9%) CTS 1(14.3%) Painless mass 1(14.3%) Painless ulcer 1(14.3%) Joint Stiffness7 (100%)	7 (100%)	7 (100%)	NA	NA	NA	HRZE x 6–18 month Splinting 1 month Physiotherapy I&D 1(14.3%) CTD 1(14.3%) Arthrotomy 1(14.3%) Tenosynovectomy2 (28.6%)	F/u 26.28 month Functional ROM (flexion and extension) achieved 6(85.7%)	Defaulter 1(14.3%) Recurrence 0%	
Tsai et al.[55] (2003)	37	38	24 to 80 (58) M 25 F 12	38 wrist 37 patient (1 B/L)	Pain 25(67.5%) Swelling 31(83.7%) Caloricity 16(43.2%) Stiffness 14(37.8%) D.S. 5(13.5%) Weakness 1(2.7%) Numbness 7(18.9%)	14 (37.8%)	37 (100%)	NA	NA	NA	HRE x 1 year CTD 1(2.7%) Arthrodesis 4(10.8%) Tenosynovectomy &debridement 37(100%)	F/u 11 year 20(54.05%) take Complete treatment Good response 17(45.9%)	Lost in f/u 16(43.24%) Death 1(2.7%) Pott's spine 1(2.7%) Contracture at wrist 1(2.7%) Recurrence 0%	Tb Pul. 17(46%) Miliary nodules 5(13.5%) Pleural effusion 2(5.4%) Infiltration of B/L lower lung 2(5.4%)
Benchakroun et al.[58] (2004)	11	11	Mean age 42 8 men & 3 women	Wrist joint 8(72.7%) TS 2(18.2%) Both 1(9%)	Pain 9(81.8%) Swelling 1(9%) Stiffness 2(18.2%) Ankylosis 1(9%) D.S. 2(18.2%) CTS 1(9.%)	5 (45.5%)	11 (100%)	5 (45.5%)	NA	NA	HRZ x 9–12 month Splint 1 month followed by physiotherapy I &D 3(27.3%)	2 year f/u Wrist mobility(ROM) Good 2(18.2%) Avg 5(45.5%) Bad 4(36.4%) Symptom Good 4(36.4%) Avg 2(18.2%) Bad 5(45.5%) Ankylosis 2(18.2%) Osteoarthritis 6(54.54%)		Pul. tb 4(36.4%) Scintigraphy tc99 revealed early stage
Ozçelik et al.[56] (2006)	3	2	16 to 21 (18.5) Both F	Both case TS	Painless 2(100%) Swelling 2(100%) D.S. 1(50%), Stiffness 0% Lymphadenopathy 1(50%).	0%	2 (100%)	2 (100%)	NA	NA	HRZS x few days HRZ x 3 month HR x 9 month Open biopsy and debridement	F/u 16–26 month ROM normal	Recurrence 0%	PPD test 3(100%) MRI showed a synovial lesion surrounding flexor tendons
Kotwal et al.[3] (2009)	32	8 wrist	9 to 65 (30.5) M 7 F 1	Capitate 2(25%) Soft tissue 6(75%)	Pain 8(100%) Swelling 8(100%) D.S. 3(37.5%) CTS 2(25%)	few	8 (100%)	NA	NA	2 (25%)	HRZE x 4 months HRZ x 3 months HR x 11 months. Splinting by slab. Debridement 3(37.5%) CTD 1(12.5%)	follow-up 23.12 months Hand function Green and O'Brien used. The mean was 58.3 (25–80) before treatment and 90.5 (80–95) at the end.		MRI showed chronic tb synovitis and joint destruction,
Dlimi et al.[16] (2011)	30	15	14 to 68 (31)	Osteoarthritis 10(66.7%) TS 5(33.3%)	Swelling 15(100%) Pain 09(60%) Fistula 07(46.7%) Stiffness 08(53.3%) Radiocarpal	10 (65%)	15 (100%)	15 (100%)	NA	NA	HRZS x 2 month HR x 9 month Cast splint for 1month Synovectomy,	Osteoarthritis group Normal function outcome 4(26.7%) Painless stiffness 4(26.7%) Lost from f/u 2(13.5%)	Relapse 0% Failure (2%) Recurrence 0%	Pul. Tb 2(13.3%) MRI showed synovial lesion To detect infra-

					Subluxation 01(13.3%)						Arthrodesis 1(6.67%) Rehabilitation after 1 month	TS group 50% showed normal functional outcome		radiological lesion Tc-99 CT scan for sequestrum & joint damage
Güner et al.[57] (2014)	3	3	57 to 66 (61.5) M 2 F 1	TS3(100%)	Pain 3(100%) Swelling 2(66%) Tenderness 1(33%), CTS 1(33%) Crepitations 1(33%)	3 (100%)	3 (100%)	NA	3 (100%)	1 (33%)	HRZE x 2 month HR x 9 month Debridement Splint in 1(33%) Repair of a ruptured tendon in 1(33%).	12–26 month Good functional outcome	No recurrence	Chest x-ray normal
Prakash et al.[41] (2017)	44	16	2 to 18 (11.3) M 24 F 20	Not given	Painless 9(56%), Pain 7(43.75%) Swelling 16(100%) D.S. 5(31%) Stiffness 16(100%)	2 (11%)	16 (100%)	Few	NA	–	HRZE x 4 months HRE x 4 months HR x 18 months Splint & slabs Debridement and curettage 13(81.25%)	F/u of 2 years. Hand function: Modified Green O'Brian (ROM) Scoring (52.7 before and 93.4 after treatment)	No recurrence	Pul. Tb 5(31.25%) MRI showed bony destruction
Zou et al.[15] (2021)	18	18	15–81 (53.5 ± 18.3) M 11 F 7	Bone involved 100%)	Pain 17(94.4%) Swelling 18(100%) Stiffness 18(100%) D.S. 2(11.1%) Numbness 4(22.2%)	Few	18 (100%)	NA	NA	NA	HRZE x 3 month HR x 9 month Curettage 15(83.3%) Arthrodesis 3(16.7%)	F/u mean 39.7 ± 15.3 month Gatland–Werley score for ROM & Function (21.73 before treatment to 5.07 after treatment) DASH score (45.87 before treatment to 6.73 after treatment) Grip strength 100%	No recurrence And drug resistance	Pul. Tb 2(11.1%) MRI & CT showing surrounding tissue destruction
Yushan et al.[4] (2022)	84	84	18-84 (46.8 ± 18.5) M 45 F 39	Bone 27 (32.1%) Capitate 7(8.3%) Lunate 5(6%) Scaphoid 4(4.8%) Ulna 6(7.1%) Radius 5(6%) Soft tissue 57 (67.9%) TS 38(45.2%) WS 19(22.6%)	Pain Swelling Stiffness Wrist mass D.S. 15(17.86%) Numbness and CTS 5(6%)	NA	NA	NA	NA	NA	Conservative 33(39.3%) HRZE x 12–18 month (No definitive duration protocol given) Surgical 51(60.7%) Arthrodesis (internal fixation) 13(15.5%) Arthrodesis (external fixation) 11(13.1%) Synovectomy 14(16.7%) I&D 13(15.5%) Followed by HRZE x 3 months HR x 9 months	Mean F/U in in month 50.8 ± 17.1 In conservative group outcome was satisfactory but in surgical group was: Quick DASH, and PRWHE decreased. VAS improved from 5.9 to 1.4, EQ-5D-5L improved from 0.36 to 0.88. EQ-VAS improved from 40.2 to 89.1	Recurrence in 2 patients one from I&D group and another from internal arthrodesis	Pul TB 9(10.7%) Previous trauma 24(28.6%) MRI suggestive of rice bodies

[Abbreviations: Avg - Average; B/L - Bilateral; CTS - Carpal tunnel syndrome; CTD - Carpal tunnel decompression; CT - Computed Tomography; DASH - Disabilities of the arm, shoulder and hand; DS - Discharging sinuses; E – Ethambutol; EPTB - Extra pulmonary tuberculosis; F - Female; F/u – Follow up; H – Isoniazid; I&D - Incision and drainage; MRI - Magnetic resonance imaging; M – Male; MDR - Multidrug resistance; NA - Not available; PAS - Para-amino salicylic acid; PPD - Purified Protein derivative; ROM - Range of motion; R - Rifampicin; S - Streptomycin; Z- Pyrazinamide, VAS= Visual Analogue Score; PRWHE- Patient Related Wrist Evaluation; and TS – Tenosynovitis].



Fig. 1. (a, b) A globular swelling of 3 × 3 cm on the dorsum of the right wrist with no gross deformity and no sign of inflammation; (c) Plain radiograph of right wrist Antero-posterior and lateral view suggestive of phemister triad (joint space narrowing, diffuse osteopenia with irregular eroded radio-carpal surface), reduction in height of carpal bones and their subluxation; (d) T2 weighted Coronal and sagittal section; suggestive of osteomyelitis, synovial thickening, radio-carpal destruction, and fluid collection along the tendon sheet.

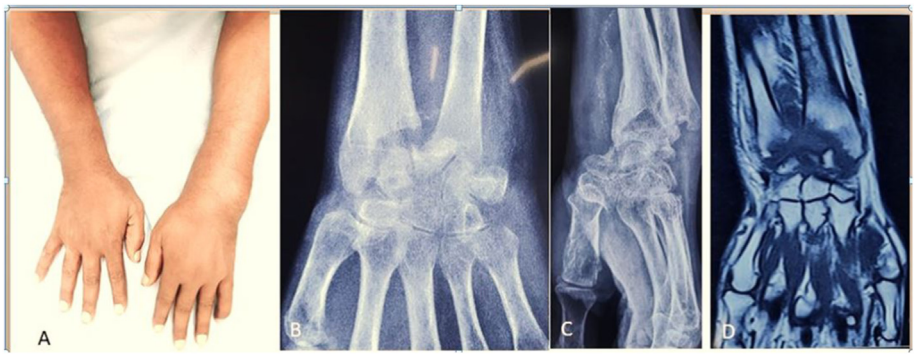

Fig. 2. (a): Clinical image showing swelling at left wrist with deformity; (b): Plain antero-posterior radiograph of wrist showing erosions, joint space narrowing with destruction of distal radio-ulna and carpals, also there is soft tissue swelling and osteopenia; (c): Plain lateral radiograph of wrist showing same finding with distal radio-ulnar joint subluxation (malalignment); (d): Non-enhanced coronal section of wrist (T2 weighted PD image) MRI showing osteomyelitis, destruction, and erosion of wrist joint.

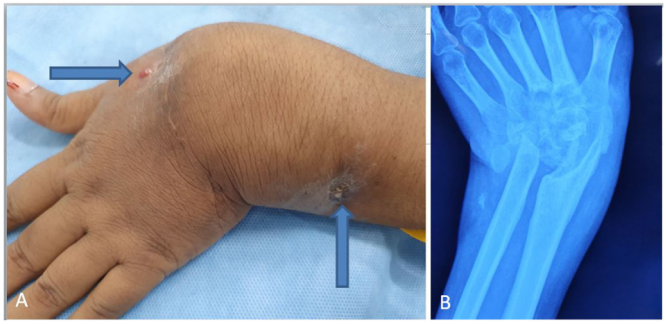

Fig. 3. (a) Clinical image showing swollen wrist, deformity with multiple sinuses. (b) Soft tissue swelling, calcification and completely destroyed joint on radiograph.

The Phemister triad such as osteoporosis in the joint bones, bone erosion in the peripheral area, and a reduction in joint space can be classically seen in patients.[17] "Kissing lesion" is sometimes also seen in the advanced stage due to severe destruction. Based on the radiological features on a plain X-ray, WJ-TB has 2 stages namely stage of synovitis and arthritis (osteopenia around the wrist joint, increased joint space, and mild to moderate subchondral erosion) and stage of erosion or destruction (gradual narrowing of joint-space, subchondral erosion, fibrous ankylosis, pathological subluxation, dislocation, and sometimes atrophic changes).[17,18]

6.2. Computerized tomography (CT)

High Resolution Computed Tomography (HRCT) is rarely required to diagnose WJ-TB. It confirms the X-ray diagnosis by having a clearer picture of the sequestrum (honeycomb appearance) and joint destruction.[18] Post-contrast scans are beneficial to find out the extension of infection and any sinus tract formation. CT of WJ-TB can show the extent of bony damage such as distorted bone, patchy density shadow, and gritty changes.[15] On CT, the presence of a geode and a joint space narrowing points towards a diagnosis of Rheumatoid Arthritis (RA) and rule out WJ-TB.[19]

6.3. Magnetic Resonance Imaging (MRI)

MRI is the best modality to reveal the extent of abscess formation and degree of soft tissue involvement in the early stage where the joint is usually preserved. Synovial thickening around the

tendons and synovial fluid collection in the tendon sheath will be visible on an MRI. These findings will appear as low signal intensity on T1-weighted images, intermediate to low signal intensity on T2, and enhancement on contrast-enhanced MR images.[5,20] A contrast-enhanced MRI study can easily differentiate TB tenosynovitis of the wrist from inflammatory arthritis.[21] Centrally located bone erosions and a lack of bone marrow enhancement on an MRI are signs of tuberculous arthritis rather than suppurative lesions.[22] Osteomyelitis and encasement of the median nerve can also be seen on MRI.[5] (Fig. 4) Rice bodies can also be demonstrated in the wrist on MRI. Bursitis may mimic ganglion with punctate calcification in the soft tissue. Tuberculous tenosynovitis (hygromatous, serofibrinous, and fungoid forms) of the flexor or extensor tendon at the wrist can be easily misdiagnosed with pyogenic infections and with inflammatory tenosynovitis and arthritis.[23,24]

6.4. Ultrasound (US)

US may be used to assess the size of an abscess and its aspiration.

7. Other radiological investigation

An earlier diagnosis may be possible using 18-Fluoro-deoxy-glucose positron emission tomography/**(18-FDG-PET) and computed tomography (18-FDG-PET/CT)** identifies more EPTB lesions than CT. This is especially useful when there is a multisite involvement. Recent modalities such as Single-photon emission computed tomography (SPECT) and 18-FDG facilitate infection at an earlier stage, and the progression of disease to an advanced stage can be reduced with appropriate treatment.[25] The detection sensitivities of Technetium 99 m (Tc 99 m) bone scans and gallium scans are high but not specific for skeletal TB, these scans can also be used to detect multiple sites in bone TB.[26]

8. Laboratory investigations

8.1. Role of arthrocentesis

Synovial fluid aspiration followed by analysis is one of the best modalities for isolating Mycobacterium Tuberculosis and confirming the diagnosis. Synovial fluid cell counts may reveal lymphocytosis, LDH, lactate, crystal, and macrophages.[27] Protein levels of Synovial fluid are increased but the glucose levels are decreased.[28]

For wrist arthrocentesis, approaches such as radiocarpal and ulnocarpal may be used for better yield. Ultrasound may be required in difficult cases, where the conventional procedure is not possible either due to low effusion volume or altered anatomy. The probe should be inserted in the sagittal view over the distal radio-scaphoid or radio-lunate area. The aspirated fluid should be sent for laboratory diagnosis of tuberculosis.

8.2. Microbiology

The sensitivity of this Ziehl-Neelsen microscopy is 48%.[29] It is an inexpensive, reliable, and reproducible method for diagnosis and monitoring. As a result, cultural sensitivity ranges from 80% to 93%. Furthermore, the specificity is very high at 98%.[30,31]

8.3. Histopathological examination

Patients with obvious bony lesions require core biopsy and soft tissue lesions should undergo needle cytology. Granulomas and acid fast bacilli (AFB) are common histopathological findings in tuberculosis. Granulomas are found on a routine basis during this investigation. Their essence provides strong evidence of tuberculosis, which is particularly useful when the culture is negative. Biopsy and fine-needle aspiration cytology (FNAC) are common sources of histopathology material, which can be amplified using PCR (polymerase chain reaction). FNAC can aid with ultrasound or CT scan for the localization of the lesion accurately. Loss of host immune function on the other hand, might suppress well-developed granulomas on histopathologic examination.[32] Granulomas can also be found in non-tuberculous mycobacterial illnesses, fungal infections, brucellosis, and syphilis. Thus pathological interpretation should be done in collaboration with clinical, radiological and microbiological examination.[33]

8.4. Molecular examination

PCR and GeneXpert are the latest modalities for detecting not



Fig. 4. (a) Plain radiograph of wrist with hand antero-posterior shows juxtra articular osteopenia, with well aligned carpal bones; (b–d) shows patchy edema in carpal bone with synovial thickening, with intra-osseous cystic changes. There is intraarticular loculated collection with median nerve compression (arrow in figure c) due to synovial thickening.

only *Mycobacterium tuberculosis* (*MTB*) DNA but also facilitating the detection of resistance against rifampicin in tissue specimens.[34] GeneXpert MTB/RIF multiplies particular sequences and patterns of the DNA of *MTB* from the rpoB (rifampicin resistant) gene using a heminested real-time polymerase chain reaction (PCR) assay. GeneXpert's rifampicin resistance (RMP) is identified by identifying the location of the rpoB gene that will be probed with the molecular beacon.[34] This examination, which includes bacteriolysis followed by amplification of the extracted nucleic acid, may all be done automatically. The system will be supplied by a disposable cartridge containing a pre-determined reagent and operated on the GeneXpert platform (Cepheid, Sunnyvale, CA).[35] GeneXpert is an easy procedure that works automatically, takes 120 min, and does not necessitate the use of an expert.[34,36] The Xpert MTB/RIF test is an automated, cartridge-based NAAT, thought to be beneficial for the fast molecular diagnosis of EPTB.[37] Several papers have described GeneXpert's effectiveness in detecting every instance of pulmonary tuberculosis. It can detect 90% of suspects, which are having negative acid-fast staining. It also has a sensitivity of 97%.[36] Denkinger et al. reported that Xpert MTB/RIF has a pooled sensitivity and specificity of 83.1% and 98.7% respectively for the detection of EPTB.[38]

8.5. Immunological tests

In patients who have had prior tuberculosis interaction, the tuberculin skin test (TST) is positive. In patients who have had a previous history of tuberculosis contact, the pure protein derivative test results are almost 100% positive.[39] **Interferon-gamma release assays** are also novel modalities based on their release after stimulation of sensitized T-cells by bacterial antigens. It has a sensitivity of 95% and a specificity of 76%, but it can't tell the difference between active and latent tuberculosis.[40] This is a supportive method for diagnosis, not a confirmative test.

8.6. Nerve conduction studies velocity

Nerve conduction studies are required in TB wrist cases presented with tingling and numbness of hand which showed delayed conduction due to compression of median nerve at the carpal tunnel.

8.7. Management of TB wrist

The difficulties and delays associated with the late diagnosis of wrist tuberculosis also result in further complications, such as finger stiffness, extreme arthritis, ankylosis, and residual deformity.[41] (Fig. 5) A better result can be anticipated with early diagnosis and treatment. Treatment options include antitubercular drugs, incision and drainage, debridement, synovectomy, and arthrodesis. Splints or plaster slabs for a short duration may be required to relieve acute symptoms.[3]

The aim of the treatment is not only to remove foci of infection with help of surgery, and pain relief with help of a slab or cast but also to avoid further complications like persistent discharge, pathological fracture, chronic pain, deformity, and carpal tunnel syndrome.

8.7.1. Anti-tubercular therapy (ATT)[42]

After a confirmed diagnosis, it is mandatory to start immediate ATT for cessation of disease progression and complications. In a recent series of 84 patients 40% patients were treated with ATT alone and rest 60% with surgery followed by ATT.[4]

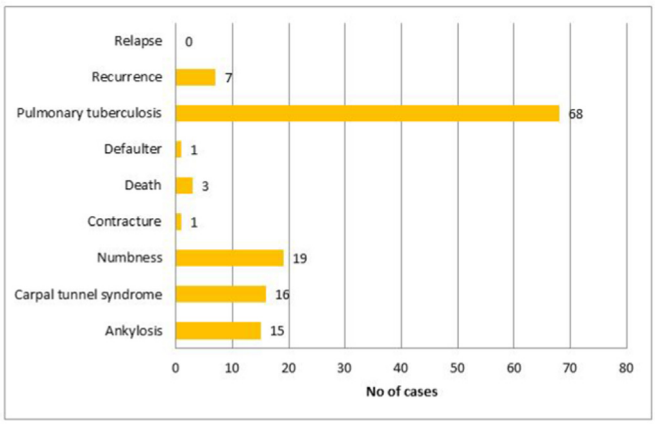

Fig. 5. Various complications of Tb wrist documented in 16 clinical studies in the literature.

8.7.2. Non-operative management

Aside from the medications described above, there are various nonoperative methods. Prolonged immobilization is not advised as it might create joint stiffness. For one month, splints or plasters are utilized, especially in a patient with wrist instability who is in the active phase of the disease. This is then followed by progressive physiotherapy which relieves pain, reduces the likelihood of deformity, and restores function.

8.7.3. *Surgical treatment for TB of the wrist joint (WJ-TB)*

The surgical treatment of the TB wrist remains controversial. However, it may aid in a patient's early functional recovery and in encouraging them to utilize their hand for the activities of daily living. Depending on the affected anatomical structures, the extent of the bony lesions, how it influences hand and wrist function, and the patient's activities of daily living, several surgical procedures are used. Radical infected tissue debridement and curettage are beneficial to remove foci. In unstable joints and highly deformed joints arthrodesis with or without use of bone grafts is the treatment of choice for alleviating pain and rehabilitation. In a recent series of wrist TB with surgically treated patients; 15.5% underwent incision and decompression, 16.7% wrist synovectomy, (28.6%) wrist joint fusion either by plating or external fixation.[4]

i. **Debridement:** Bush et al.[43] suggested that debridement is necessary in almost every infected case which decreases the bacterial load localized in the joint. However other literature suggested that surgical curettage should be performed in noncompliant patients with 4–5 months of chemotherapy. Without prior use of chemotherapy, the infection can be disseminated and erosion of bones around the joint can occur.[14] Prakash et al.[44] and Jaovisidha et al.[11] suggested that the use of a multidrug regimen for 12–18 months is sufficient to cure the disease without any surgery. Granuloma and rice bodies should be excised after tendon sheath incision in patients with flexor or extensor tendon tenosynovitis. The lax tendons need to be plicated adjusting after proper tension. Repairing any tendon problems is also necessary.[45]

ii. **Tenosynovectomy with extensive curettage** followed by lavage is advised by different authors but some other advice that alone decompression without excision of the tendon sheath is sufficient. Because excessive removal of the soft tissue can cause instability and there may be a need for

reconstructive surgery in the future.[23,45] Patients who have symptoms of carpal tunnel syndrome should have a tenosynovectomy and carpal tunnel release as soon as feasible, followed with ATT.[46]

iii. **Arthrodesis:** Wrist arthrodesis can achieve satisfactory results in the treatment of severe wrist TB.[4] It is a better procedure for ankylosed non-functional wrists infected by TB. A Kirschner wire (K wire) or 3.5 mm dynamic compression plate is used to fix the joint in 10–15° of dorsiflexion and slightly ulnar deviated to perform a better handgrip. Although osteotomy followed by bone grafting facilitates early fusion of the wrist. However, it is controversial in some studies. All infective tissue should be removed during the procedure.[47] Brashear et al.[48] (60% cases) Benkeddache et al.[49] (25% cases), and Zou et al.[15] (16.7% cases) suggested in their studies that wrist arthrodesis is a better choice in the destructive wrist joint. Although nowadays with advanced antitubercular drugs there are fewer morbid conditions and the requirement for arthrodesis is decreased.

iv. **Arthroplasty:** Total wrist arthroplasty is superior for achieving painless, mobile, and stable joints in patients with end-stage TB wrist. There are no records in the literature for total wrist arthroplasty in the case of TB wrist

v. **Arthroscopy:** It is a better option not only for diagnostic purposes but also for debridement and collection of infective soft tissue. So far 0.9%–1.1% of serious complications were reported.[50,51] Arthroscopy can be performed to acquire synovial samples for diagnostic purposes, and additionally in individuals who are refractory to chemotherapy or may warrant additional arthroscopic synovectomy. Kotwal et al. reported good outcomes with arthroscopic wrist synovectomy and flexors tenosynovectomy in 12.5% of cases.[3]

8.7.3.1. Suggestions for surgical indication. Patients with confirmed wrist TB who have not responded to a standard ATT for eight weeks or who have an overt radiographic sequestrum with a large abscess and compromised hand function (Fig. 6). Even after receiving effective ATT, patients who have significant wrist joint dysfunction are advised to have surgery to improve their functional outcome.[4]

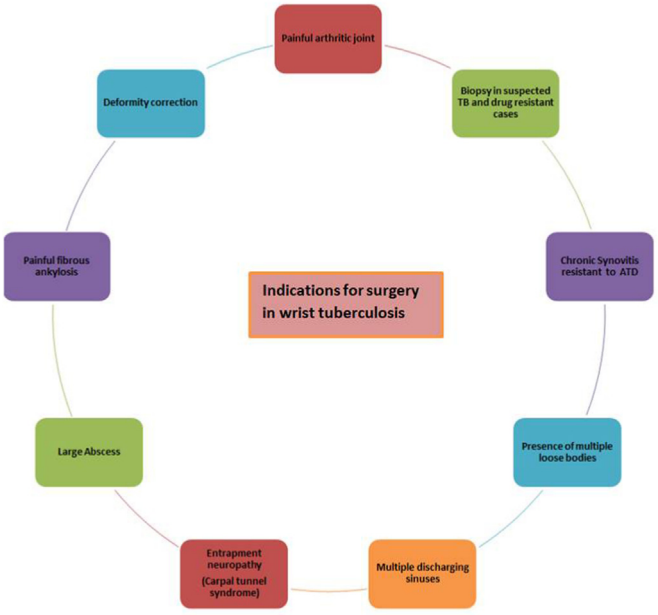

Fig. 6. Indications of surgical treatment in TB wrist patients.

8.7.3.2. Prognosis and clinical outcomes. ATT provide satisfactory results if the patients present in the early stage. Irregular postoperative ATT and a history of intra-articular steroid contribute to recurrence.[4,52] The clinical outcome depends on the on-time of the patient presenting after the symptoms. Out of 15 studies (201 cases and 205 wrists), 10 studies commented on recurrence,[3,8,9,15,44,53–57] and the relapse rate was commented on by one study which was 0%.[16] On the ankylosis 2 out of 15 studies commented and a total of 15 cases (7.4%) were reported. However, Benchakroun et al.[58] reported 2 cases of ankylosis, and Robins et al.[53] reported a total of 13 cases of ankylosis. Out of these 13 cases, 9 were fibrous ankylosed and 4 were spontaneously ankylosed.

8.7.3.3. Range of motion. After treatment, functional ROM was mentioned in 10 of the 15 studies.[8,9,15,43,44,49,53,54,56,58] In Tenosynovectomy patients (3 cases), Brashear et al. observed a deterioration in ROM after a 10-year follow-up.

To assess hand function and ROM, Leung et al.[8] utilized the criteria established by Bickel in 1953. An “excellent result” means that the patient is in good overall health, that no recurrence has occurred, and that there is no pain or edema. There is no restriction on hand activity or motion. A superior result is referred to as a “good result” (0% case). Individuals who have achieved a favorable outcome are referred to as “fair results” (25% cases). However, a “poor result” demonstrates impaired hand function as well as persistent swelling and pain (50% cases).

After therapy, Benkeddache et al.,[49] Bush et al.[43] (50%), and Ozçelik et al.[56] found normal ROM at the wrist. After a two-year follow-up, Visuthikosol et al.[9] discovered an improvement in all 14 patients (16 wrists). Patients belonging to the surgical group improved faster as compared to those in the non-surgical group in this study. In a mean follow-up of 26.28 months, Skoll et al. found improvement in ROM in 6 cases. Benchakroun et al.[58] found post-treatment ROM good in 18.2% and average in 45.5% of cases. Prakash et al.[44] and Zou et al.[15] used the score to calculate ROM in the follow-up period, it was the Modified green O′ Brian and Gartland–Werley score respectively. The outcome of these studies was excellent as per their scores. The Green and O'Brien Score was used by Kotwal et al. to assess hand function. Before therapy, the mean was 58.3 (25–80) and after the intervention, it was 90.5 (80–95).[3] The EQ-5D-5L utility index increased from 0.36 to 0.88, the visual analogue scale (VAS) improved from 5.9 to 1.4, and the EQ-VAS improved from 40.2 to 89.1 at the last follow-up at 2 years. All patients' Quick DASH and Patient Rated Wrist/Hand Evaluation (PRWHE) scores also considerably decreased.[4]

Out of 16 studies we found in the literature (ref Table 1), 10 studies suggested that the patient with TB wrist was also suffering from pulmonary TB. The incidence of pulmonary TB in the studies was 29.4% (59 cases). Only one case was a defaulter. Death was reported in 1.5% of cases due to which patients lost in the follow-up period. Apart from above mention symptoms, numbness was reported in 14 cases (5.47%) and Carpal tunnel syndrome was also reported in 11 cases (6.96%). Carpal tunnel decompression was done to relieve symptoms.

9. Conclusion

Characteristics features associated with *Mycobacterium Tuberculosis Infection of the Wrist Joint* (WJ-TB) in comparison with other musculoskeletal (MSK) TB are

1. Osteoarticular Tuberculosis (TB) of wrist joint is a rare and often misdiagnosed.

2. Though MSK -TB accounts for 20–40% of all extrapulmonary TB cases and 1–3% of all TB cases, WJ-TB represents less than 1% of total disease burden.
3. Rarer than those found in weight bearing joints and those in the Upper limb (Elbow TB more common).
4. Coincidental trauma or injury brings the condition to attention. More than a quarter of patients (About 28%) present with such a history.
5. The Wrist joint is an ellipsoid joint including three distinct joints: the distal radio-ulnar, the radio-carpal, the midcarpal joints and surrounding soft tissue envelope made of ligaments and tendons. This unique anatomical features allows *Mycobacterium Tuberculosis Infection of the Wrist Joint (WJ-TB)* to present as either a predominantly osseous/soft tissue and or as a combined clinical presentation.
6. Due to its indolent nature, a high index of suspicion, clinical evaluation, and complementary investigations are necessary to detect it in the early stages and direct effective management.
7. Though the general principles of treatment of tuberculosis at the wrist are similar to those at other osteoarticular sites and consist of appropriate ATT for at least 12 months. Specifically, for the Wrist Joint: a splint in dorsiflexion and forearm in mid-prone position may be given for 2–4 weeks to relieve pain and spasm. The wrist should be mobilized with intermittent hinged braces as soon as pain is relieved to prevent carpal collapse and subsequent deformities. TB wrist patients should be watched for signs of nerve entrapment, instability, the development of large abscesses, and deformities that require early surgical treatment.

Funding

The authors declare that no funds, grants, or other support were received during the preparation of this manuscript.

Consent to participate and publish

Not applicable.

Authorship contribution

MS, NJ, TH, MJ, VKJ: Methodology, Formal analysis and investigation, Writing - original draft preparation, making of table **KPI** Conceptualization, Methodology, Writing - review and editing, **MS, NJ, TH, MJ, VKJ** Methodology, Writing - review and editing, Resources, **VKJ, KPI, MJ** Conceptualization, Methodology, Writing - review and editing, Resources, Supervision.

Declaration of competing interest

The authors declare that they have no known competing financial interests or personal relationships that could have appeared to influence the work reported in this paper.

Acknowledgments

None.

References

1. Bayram S, Erşen A, Altan M, Durmaz H. Tuberculosis tenosynovitis with multiple rice bodies of the flexor tendons in the wrist: a case report. *Int J Surg Case Rep*. 2016;27:129–132. https://doi.org/10.1016/j.ijscr.2016.08.021.
2. Wright T, Sundaram M, McDonald D. Radiologic case study. Tuberculous osteomyelitis and arthritis. *Orthopedics*. 1996;19(8):699–702. https://doi.org/10.3928/0147-7447-19960801-19.
3. Kotwal PP, Khan SA. Tuberculosis of the hand: clinical presentation and functional outcome in 32 patients. *J Bone Joint Surg Br*. 2009;91(8):1054–1057. https://doi.org/10.1302/0301-620X.91B8.22074.
4. Yushan M, Yalikun A, Hamiti Y, Lu C, Yusufu A. Clinical features and treatment outcome of wrist tuberculosis in adult- a retrospective study of 84 consecutive cases with minimum of 2 years follow up. *BMC Muscoskel Disord*. 2022;23(1):618. https://doi.org/10.1186/s12891-022-05563-8.
5. Hsu CY, Lu HC, Shih TTF. Tuberculous infection of the wrist: MRI features. *AJR Am J Roentgenol*. 2004;183(3):623–628. https://doi.org/10.2214/ajr.183.3.1830623.
6. Hassanpour SE, Gousheh J. Mycobacterium tuberculosis-induced carpal tunnel syndrome: management and follow-up evaluation. *J Hand Surg Am*. 2006;31(4):575–579. https://doi.org/10.1016/j.jhsa.2005.01.018.
7. Low SY, Hsu A, Eng P. Interventional bronchoscopy for tuberculous tracheobronchial stenosis. *Eur Respir J*. 2004;24(3):345–347. https://doi.org/10.1183/09031936.04.00003604.
8. Leung PC. Tuberculosis of the hand. *Hand*. 1978;10(3):285–291. https://doi.org/10.1016/s0072-968x(78)80052-7.
9. Visuthikosol V, Kruavit A, Nitiyanant P, Siriwongpairat P. Tuberculous infection of the hand and wrist. *Ann Plast Surg*. 1996;37(1):55–59. https://doi.org/10.1097/00000637-199607000-00009.
10. Cramer K, Seiler JG, Milek MA. Tuberculous tenosynovitis of the wrist. Two case reports. *Clin Orthop Relat Res*. 1991;(262):137–140.
11. Jaovisidha S, Chen C, Ryu KN, et al. Tuberculous tenosynovitis and bursitis: imaging findings in 21 cases. *Radiology*. 1996;201(2):507–513. https://doi.org/10.1148/radiology.201.2.8888250.
12. Jain AK. Tuberculosis of the skeletal system. *Indian J Orthop*. 2016;50(3):337.
13. Jain AK. Tuberculosis of the skeletal system (bones, joints, spine and bursal sheaths). *Indian J Orthop*. 2010;44(3):356.
14. Tuli SM. *Tuberculosis of the Skeletal System (Bones, Joints, Spine and Bursal Sheaths)*. jaypee; 2016. https://www.jaypeedigital.com/book/9789385891199. Accessed April 9, 2023.
15. Zou L, Guo X, Xue H, Huang D, Lv H, Tan M. Wrist tuberculosis-experience from eighteen cases: a retrospective study. *J Orthop Surg Res*. 2021;16(1):37. https://doi.org/10.1186/s13018-020-02198-0.
16. Dlimi F, Bellarbi S, Mahfoud M, Berrada MS, El Bardouni A, El Yaacoubi M. [Tuberculosis of the hand and wrist: different aspects of 30 cases]. *Chir Main*. 2011;30(3):198–204. https://doi.org/10.1016/j.main.2011.04.006.
17. De Vuyst D, Vanhoenacker F, Gielen J, Bernaerts A, De Schepper AM. Imaging features of musculoskeletal tuberculosis. *Eur Radiol*. 2003;13(8):1809–1819. https://doi.org/10.1007/s00330-002-1609-6.
18. Vanhoenacker FM, Sanghvi DA, De Backer AI. Imaging features of extraaxial musculoskeletal tuberculosis. *Indian J Radiol Imag*. 2009;19(3):176–186. https://doi.org/10.4103/0971-3026.54873.
19. Latief W, Asril E. Tuberculosis of the wrist mimicking rheumatoid arthritis – a rare case. *Int J Surg Case Rep*. 2019;63:13–18. https://doi.org/10.1016/j.ijscr.2019.08.023.
20. Bagir M, Sayit E. Tuberculous tenosynovitis of the wrist: a report of two cases with special reference to magnetic resonance findings. *Curr Med Imag Rev*. 2019;15(5):517–520. https://doi.org/10.2174/1573405614666180919141141.
21. Tehranzadeh J, Ashikyan O, Anavim A, Tramma S. Enhanced MR imaging of tenosynovitis of hand and wrist in inflammatory arthritis. *Skeletal Radiol*. 2006;35(11):814–822. https://doi.org/10.1007/s00256-006-0129-x.
22. Hong SH, Kim SM, Ahn JM, Chung HW, Shin MJ, Kang HS. Tuberculous versus pyogenic arthritis: MR imaging evaluation. *Radiology*. 2001;218(3):848–853. https://doi.org/10.1148/radiology.218.3.r01fe27848.
23. Sanders CJ, Schucany WG. Tuberculous tenosynovitis. *SAVE Proc*. 2008;21(1):71–72.
24. Suwannaphisit S, Ranong NN. Tuberculous tenosynovitis of the Flexor Tendons of the hand and wrist: a case report and mini-review. *Ann Med Surg (Lond)*. 2020;57:249–252. https://doi.org/10.1016/j.amsu.2020.07.061.
25. Yu WY, Lu PX, Assadi M, et al. Updates on 18F-FDG-PET/CT as a clinical tool for tuberculosis evaluation and therapeutic monitoring. *Quant Imag Med Surg*. 2019;9(6):1132–1146. https://doi.org/10.21037/qims.2019.05.24.
26. Lin WY, Wang SJ, Cheng KY, Shen YY, Changlai SP. Diagnostic value of bone and Ga-67 imaging in skeletal tuberculosis. *Clin Nucl Med*. 1998;23(11):743–746. https://doi.org/10.1097/00003072-199811000-00004.
27. Abay F, Yalew A, Shibabaw A, Enawgaw B. Hematological abnormalities of pulmonary tuberculosis patients with and without HIV at the university of gondar hospital, Northwest Ethiopia: a comparative cross-sectional study. *Tuberc Res Treat*. 2018;2018:5740951. https://doi.org/10.1155/2018/5740951.
28. Rajakumar D, Rosenberg AM. Mycobacterium tuberculosis monoarthritis in a child. *Pediatr Rheumatol Online J*. 2008;6:15. https://doi.org/10.1186/1546-0096-6-15.
29. Shah MI, Mishra S, Yadav VK, et al. Ziehl–Neelsen sputum smear microscopy image database: a resource to facilitate automated bacilli detection for tuberculosis diagnosis. *J Med Imaging*. 2017;4(2):027503. https://doi.org/10.1117/1.JMI.4.2.027503.
30. Broderick C, Hopkins S, Mack DJF, et al. Delays in the diagnosis and treatment of bone and joint tuberculosis in the United Kingdom. *Bone Joint Lett J*. 2018;100-B(1):119–124. https://doi.org/10.1302/0301-620X.100B1.BJJ-2017-0357.R1.
31. Chitnis AS, Jaganath D, Gish RG, Wong RJ. Diagnosis and treatment of latent tuberculosis infection. *Official journal of the American College of Gastroenterology | ACG*. 2021;116(11):2155. https://doi.org/10.14309/

ajg.0000000000001398.
32. de Noronha ALL, Báfica A, Nogueira L, Barral A, Barral-Netto M. Lung granulomas from Mycobacterium tuberculosis/HIV-1 co-infected patients display decreased in situ TNF production. *Pathol Res Pract*. 2008;204(3):155–161. https://doi.org/10.1016/j.prp.2007.10.008.
33. Zumla A, James DG. Granulomatous infections: etiology and classification. *Clin Infect Dis*. 1996;23(1):146–158. https://doi.org/10.1093/clinids/23.1.146.
34. Massi MN, Biatko KT, Handayani I, et al. Evaluation of rapid GeneXpert MTB/RIF method using DNA tissue specimens of vertebral bones in patients with suspected spondylitis TB. *J Orthop*. 2017;14(1):189–191. https://doi.org/10.1016/j.jor.2016.12.003.
35. Raja S, Ching J, Xi L, et al. Technology for automated, rapid, and quantitative PCR or reverse transcription-PCR clinical testing. *Clin Chem*. 2005;51(5):882–890. https://doi.org/10.1373/clinchem.2004.046474.
36. Boehme CC, Nabeta P, Hillemann D, et al. Rapid molecular detection of tuberculosis and rifampin resistance. *N Engl J Med*. 2010;363(11):1005–1015. https://doi.org/10.1056/NEJMoa0907847.
37. Kim YW, Kwak N, Seong MW, et al. Accuracy of the Xpert® MTB/RIF assay for the diagnosis of extra-pulmonary tuberculosis in South Korea. *Int J Tubercul Lung Dis*. 2015;19(1):81–86. https://doi.org/10.5588/ijtld.14.0500.
38. Denkinger CM, Schumacher SG, Boehme CC, Dendukuri N, Pai M, Steingart KR. Xpert MTB/RIF assay for the diagnosis of extrapulmonary tuberculosis: a systematic review and meta-analysis. *Eur Respir J*. 2014;44(2):435–446. https://doi.org/10.1183/09031936.00007814.
39. Lee JY. Diagnosis and treatment of extrapulmonary tuberculosis. *Tuberc Respir Dis*. 2015;78(2):47–55. https://doi.org/10.4046/trd.2015.78.2.47.
40. Kim SH, Cho OH, Park SJ, et al. Rapid diagnosis of tuberculous meningitis by T cell-based assays on peripheral blood and cerebrospinal fluid mononuclear cells. *Clin Infect Dis*. 2010;50(10):1349–1358. https://doi.org/10.1086/652142.
41. Prakash J, Mehtani A. Hand and wrist tuberculosis in paediatric patients - our experience in 44 patients. *J Pediatr Orthop B*. 2017;26(3):250–260. https://doi.org/10.1097/BPB.0000000000000325.
42. Jilani TN, Avula A, Zafar Gondal A, Siddiqui AH. Active tuberculosis. In: *StatPearls*. StatPearls Publishing; 2023. http://www.ncbi.nlm.nih.gov/books/NBK513246/. Accessed April 9, 2023.
43. Bush DC, Schneider LH. Tuberculosis of the hand and wrist. *J Hand Surg Am*. 1984;9(3):391–398. https://doi.org/10.1016/s0363-5023(84)80230-0.
44. Prakash J, Mehtani A. Isolated tuberculosis of scaphoid in the skeletally immature: a rare cause of chronic wrist pain. *BMJ Case Rep*. 2015;2015:bcr2015209569. https://doi.org/10.1136/bcr-2015-209569.
45. Lall H, Nag SK, Jain VK, Khare R, Mittal D. Tuberculous extensor tenosynovitis of the wrist with extensor pollicis longus rupture: a case report. *J Med Case Rep*. 2009;3(1):142. https://doi.org/10.1186/1752-1947-3-142.
46. Kumar R, Lakkireddy M, Maley D, Eppakayala S, Sathu S, Kashyap A. Flexor tenosynovitis of the wrist with carpal tunnel syndrome. *Int J Mycobacteriol*. 2023;12(1):100–102. https://doi.org/10.4103/ijmy.ijmy_201_22.
47. Jimenez A, Anand P. Wrist arthrodesis. In: *StatPearls*. StatPearls Publishing; 2023. http://www.ncbi.nlm.nih.gov/books/NBK556015/. Accessed April 9, 2023.
48. Brashear HR, Winfield HG. Tuberculosis of the wrist: a report of ten cases. *South Med J*. 1975;68(11):1345–1349. https://doi.org/10.1097/00007611-197511000-00006.
49. Benkeddache Y, Gottesman H. Skeletal tuberculosis of the wrist and hand: a study of 27 cases. *J Hand Surg Am*. 1982;7(6):593–600. https://doi.org/10.1016/s0363-5023(82)80109-3.
50. Slutsky DJ, Nagle DJ. Wrist arthroscopy: current concepts. *J Hand Surg Am*. 2008;33(7):1228–1244. https://doi.org/10.1016/j.jhsa.2008.07.015.
51. Leclercq C, Mathoulin C, Members of EWAS. Complications of wrist arthroscopy: a multicenter study based on 10,107 arthroscopies. *J Wrist Surg*. 2016;5(4):320–326. https://doi.org/10.1055/s-0036-1584163.
52. Chandrasekharan J, Sambandam SN, Cheriyakara S, Mounasamy V. Tuberculous tenosynovitis presenting as finger drop: a case report and a systematic review of the literature. *Muscles, Ligaments and Tendons Journal*. 2016;6(2):258. https://doi.org/10.11138/mltj/2016.6.2.258.
53. Robins RH. Tuberculosis of the wrist and hand. *Br J Surg*. 1967;54(3):211–218. https://doi.org/10.1002/bjs.1800540314.
54. Skoll PJ, Hudson DA. Tuberculosis of the upper extremity. *Ann Plast Surg*. 1999;43(4):374–378. https://doi.org/10.1097/00000637-199910000-00005.
55. Tsai MS, Liu JW, Chen WS, de Villa VH. Tuberculous wrist in the era of effective chemotherapy: an eleven-year experience. *Int J Tubercul Lung Dis*. 2003;7(7):690–694.
56. Ozçelik IB, Aydin A, Sezer I, Oztaş S. [Treatment algorithm in synovial tuberculosis of the hand and wrist: a report of three cases]. *Acta Orthop Traumatol Turcica*. 2006;40(3):255–259.
57. Güner MD, Bektaş U, Akmeşe R, Kamburoğlu HO, Armangil M, Ay Ş. Wrist tenosynovitis due to Mycobacterium bovis infection: case series and review of the literature. *Plast Reconstr Surg Glob Open*. 2015;2(12):e262. https://doi.org/10.1097/GOX.0000000000000238.
58. Benchakroun M, El Bardouni A, Zaddoug O, et al. [Tuberculosis of the wrist. Symptoms and outcome in eleven cases]. *Rev Chir Orthop Reparatrice Appar Mot*. 2004;90(4):337–345. https://doi.org/10.1016/s0035-1040(04)70129-4.

Update

Journal of Clinical Orthopaedics and Trauma

Volume 74, Issue , March 2026, Page

DOI: https://doi.org/10.1016/j.jcot.2025.103312

Journal of Clinical Orthopaedics and Trauma 74 (2026) 103312

Contents lists available at ScienceDirect

Journal of Clinical Orthopaedics and Trauma

journal homepage: www.elsevier.com/locate/jcot

Erratum regarding missing peer review statement in previously published articles

Owing to a Publisher error, peer review statement was not included in the published versions of the following articles, that appeared in previous issues of Journal of Clinical Orthopaedics and Trauma.

The appropriate peer review statements, for each article are provided below.

1. "Correlation between height and semitendinosus tendon length, prediction of minimum semitendinosus tendon length based on height-an easy and accurate method" (Journal of Clinical Orthopaedics and Trauma., 31 (2022) 101918) https://doi.org/10.1016/j.jcot.2022.101918

Peer review statement: The author list of this article includes an editorial board members, namely Ankit Goyal and Hitesh Lal. We would like to note that they were not involved in the peer review process or any of the decision-making steps of the manuscript.

2. "Cystic bone Lesions: Diagnostic pitfalls and therapeutic considerations" (Journal of Clinical Orthopaedics and Trauma., 67 (2025) 103046) https://doi.org/10.1016/j.jcot.2025.103046

Peer review statement: The author list of this article includes an editorial board member, namely Ashish Gulia. We would like to note that they were not involved in the peer review process or any of the decision-making steps of the manuscript.

3. "Artificial intelligence-based orthopaedic perpetual design" (Journal of Clinical Orthopaedics and Trauma., 49 (2024) 102356) https://doi.org/10.1016/j.jcot.2024.102356

Peer review statement: The author list of this article includes an editorial board members, namely Abid Haleem, Abhishek Vaish and Raju Vaishya. We would like to note that they were not involved in the peer review process or any of the decision-making steps of the manuscript.

4. "Gut Microbiome - Should we treat the gut and not the bones?" (Journal of Clinical Orthopaedics and Trauma., 39 (2023) 102149) https://doi.org/10.1016/j.jcot.2023.102149

Peer review statement: The author list of this article includes an editorial board member, namely Vijay Kumar Jain. We would like to note that they were not involved in the peer review process or any of the decision-making steps of the manuscript.

5. "Decoding the hidden realm: Molecular pioneering unravelling osteoarticular tuberculosis diagnosis" (Journal of Clinical Orthopaedics and Trauma., 56 (2024) 102538) https://doi.org/10.1016/j.jcot.2024.102538

Peer review statement: The author list of this article includes an editorial board members, namely Vijay Kumar Jain and Kartikeyan Iyengar. We would like to note that they were not involved in the peer review process or any of the decision-making steps of the manuscript.

6. "Trends of publications on primary sarcomas of bone: A bibliometric analysis" (Journal of Clinical Orthopaedics and Trauma., 63 (2025) 102917) https://doi.org/10.1016/j.jcot.2025.102917

Peer review statement: The author list of this article includes an editorial board members, namely Vibhu Krishnan Viswanathan, Mohit Kumar Patralekh, Vijay Kumar Jain, Madhan Jeyaraman and Kartikeyan Iyengar. We would like to note that they were not involved in the peer review process or any of the decision-making steps of the manuscript.

7. "Bacteriophage therapy in infection after fracture fixation (IAFF) in orthopaedic surgery" (Journal of Clinical Orthopaedics and Trauma., 35 (2022) 102067) https://doi.org/10.1016/j.jcot.2022.102067

Peer review statement: The author list of this article includes an editorial board members, namely Vijay Kumar Jain and Karthikeyan Iyengar. We would like to note that they were not involved in the peer review process or any of the decision-making steps of the manuscript.

8. "Combating antimicrobial resistance in osteoarticular infections: Current strategies and future directions" (Journal of Clinical Orthopaedics and Trauma., 58 (2024) 102791) https://doi.org/10.1016/j.jcot.2024.102791

Peer review statement: The author list of this article includes an editorial board member, namely Vijay Kumar Jain. We would like to note that they were not involved in the peer review process or any of the decision-making steps of the manuscript.

9. "*Mycobacterium Tuberculosis* infection of the wrist joint: A current concepts review" (Journal of Clinical Orthopaedics and Trauma., 44 (2023) 102257) https://doi.org/10.1016/j.jcot.2023.102257

Peer review statement: The author list of this article includes an editorial board members, namely Kartikeyan Iyengar and Vijay Kumar Jain. We would like to note that they were not involved in the

DOIs of original article: https://doi.org/10.1016/j.jcot.2025.102917, https://doi.org/10.1016/j.jcot.2024.102791, https://doi.org/10.1016/j.jcot.2025.103046, https://doi.org/10.1016/j.jcot.2024.102356, https://doi.org/10.1016/j.jcot.2022.102067, https://doi.org/10.1016/j.jcot.2023.102145, https://doi.org/10.1016/j.jcot.2022.101918, https://doi.org/10.1016/j.jcot.2024.102538, https://doi.org/10.1016/j.jcot.2023.102149, https://doi.org/10.1016/j.jcot.2023.102257, https://doi.org/10.1016/j.jcot.2024.102903.

https://doi.org/10.1016/j.jcot.2025.103312

Available online 11 December 2025
0976-5662/© 2025

peer review process or any of the decision-making steps of the manuscript.

10. "Bone graft tuberculosis outbreak in USA: Is it a concern in India?" (Journal of Clinical Orthopaedics and Trauma., 39 (2023) 102145) https://doi.org/10.1016/j.jcot.2023.102145

Peer review statement: The author list of this article includes an editorial board members, namely Vijay Kumar Jain and Raju Vaishya. We would like to note that they were not involved in the peer review process or any of the decision-making steps of the manuscript.

11. "Letter to editor: Sathyendra et al. Comparative study of local injections of autologous platelet rich plasma versus corticosteroid in management of chronic plantar fasciitis" (Journal of Clinical Orthopaedics and Trauma., 62 (2025) 102903) https://doi.org/10.1016/j.jcot.2024.102903

Peer review statement: The author list of this article includes an editorial board member, namely Madhan Jeyaraman. We would like to note that they were not involved in the peer review process or any of the decision-making steps of the manuscript.