Travel Medicine and Infectious Disease 54 (2023) 102614

Contents lists available at ScienceDirect

Travel Medicine and Infectious Disease

journal homepage: www.elsevier.com/locate/tmaid

A proposed management classification for spinal brucellosis from India

Naveen Jeyaraman [a], Madhan Jeyaraman [b], Arulkumar Nallakumarasamy [c], Shanmugapriya K [d], Suraj Adhikari [e], Rishikesh Rijal [f], Ankush Asija [g], Yub Raj Sedhai [h], Sanjit Sah [i,j], Aroop Mohanty [k], D. Katterine Bonilla-Aldana [l,*], Ranjit Sah [m,n,o]

[a] Department of Orthopaedics, Shri Sathya Sai Medical College and Research Institute, Sri Balaji Vidyapeeth, Chengalpet, 603108, Tamil Nadu, India
[b] Department of Orthopaedics, ACS Medical College and Hospital, Dr MGR Educational and Research Institute, Chennai, 600056, Tamil Nadu, India
[c] Department of Orthopaedics, All India Institute of Medical Sciences, Bhubaneswar, 751019, Odisha, India
[d] Department of Respiratory Medicine, Sri Lalithambigai Medical College and Hospital, Dr MGR Educational and Research Institute, Chennai, 600095, Tamil Nadu, India
[e] Manipal College of Medical Sciences, Pokhara, Nepal
[f] Department of Gastroenterology, University of Louisville, Kentucky, USA
[g] WVU United Hospital Center, Bridgeport, WV, USA
[h] Division of Pulmonary Disease and Critical Care Medicine, University of Kentucky College of Medicine, Bowling Green, KY, USA
[i] Research Scientist, Global Consortium for Public Health and Research, Datta Meghe Institute of Higher Education and Research, Jawaharlal Nehru Medical College, Wardha, 442001, India
[j] SR Sanjeevani Hospital Kalyanpur-10, Siraha, Nepal
[k] Department of Clinical Microbiology, All India Institute of Medical Sciences, Gorakhpur, 273008, Uttar Pradesh, India
[l] Research Unit, Universidad Continental, Huancayo, Peru
[m] Tribhuvan University Teaching Hospital, Kathmandu, 46000, Nepal
[n] Department of Clinical Microbiology, Dr. D. Y. Patil Medical College, Hospital and Research Centre, Dr. D. Y. Patil Vidyapeeth, Pune, 411000, Maharashtra, India
[o] Department of Public Health Dentistry, Dr. D.Y. Patil Dental College and Hospital, Dr. D.Y. Patil Vidyapeeth, Pune, 411018, Maharashtra, India

ARTICLE INFO

Keywords:
Brucellosis
Zoonosis
Osteoarticular
Spinal
Spondylodiscitis

ABSTRACT

Introduction: The myriad presentation of osteoarticular brucellosis make the patient seek the help of general practitioners, orthopaedic and rheumatology specialists. Moreover, the lack of disease-specific symptomatology is the leading cause of the delay in diagnosing osteoarticular brucellosis. Given the increasing number of spinal brucellosis cases across the country, no literature is presented on the systematic management of spinal brucellosis. However, with our experience, we formulated a classification for managing spinal brucellosis.

Methods: A single-centred prospective observational study was conducted with 25 confirmed cases of spinal brucellosis. Patients were analysed and graded clinically, serologically, and radiologically and were managed with antibiotics for 10–12 weeks, and if necessary, stabilisation and fusion were done based on the treatment classification devised. All patients were followed up to ensure disease clearance at serial follow-up with relevant investigations.

Results: The mean age of the study participants was 52.16 ± 12.53 years. According to spondylodiscitis severity code (SSC) grading, four patients belong to grades 1, 12 to grade 2 and 9 to grade 3 at presentation. Erythrocyte sedimentation rate ($p = 0.02$), c-reactive protein ($p < 0.001$), *Brucella* agglutination titers ($p < 0.001$), and radiological outcomes improved statistically by six months. The treatment duration was individualised according to the patient's response to the treatment, with a mean time of 11.42 ± 2.66 weeks. The mean follow-up period was 14.42 ± 8 months.

Conclusion: High index of suspicion of patients from endemic regions, proper clinical assessment, serological evaluation, radiological assessment, appropriate decision-making (medical/surgical) in treatment, and regular follow-up were the key to successful comprehensive management of spinal brucellosis.

* Corresponding author. Research Unit, Universidad Continental, Huancayo, Peru.
E-mail address: dbonilla@continental.edu.pe (D.K. Bonilla-Aldana).

https://doi.org/10.1016/j.tmaid.2023.102614
Received 24 May 2023; Received in revised form 17 June 2023; Accepted 20 June 2023
Available online 29 June 2023
1477-8939/© 2023 The Authors. Published by Elsevier Ltd. This is an open access article under the CC BY-NC-ND license (http://creativecommons.org/licenses/by-nc-nd/4.0/).

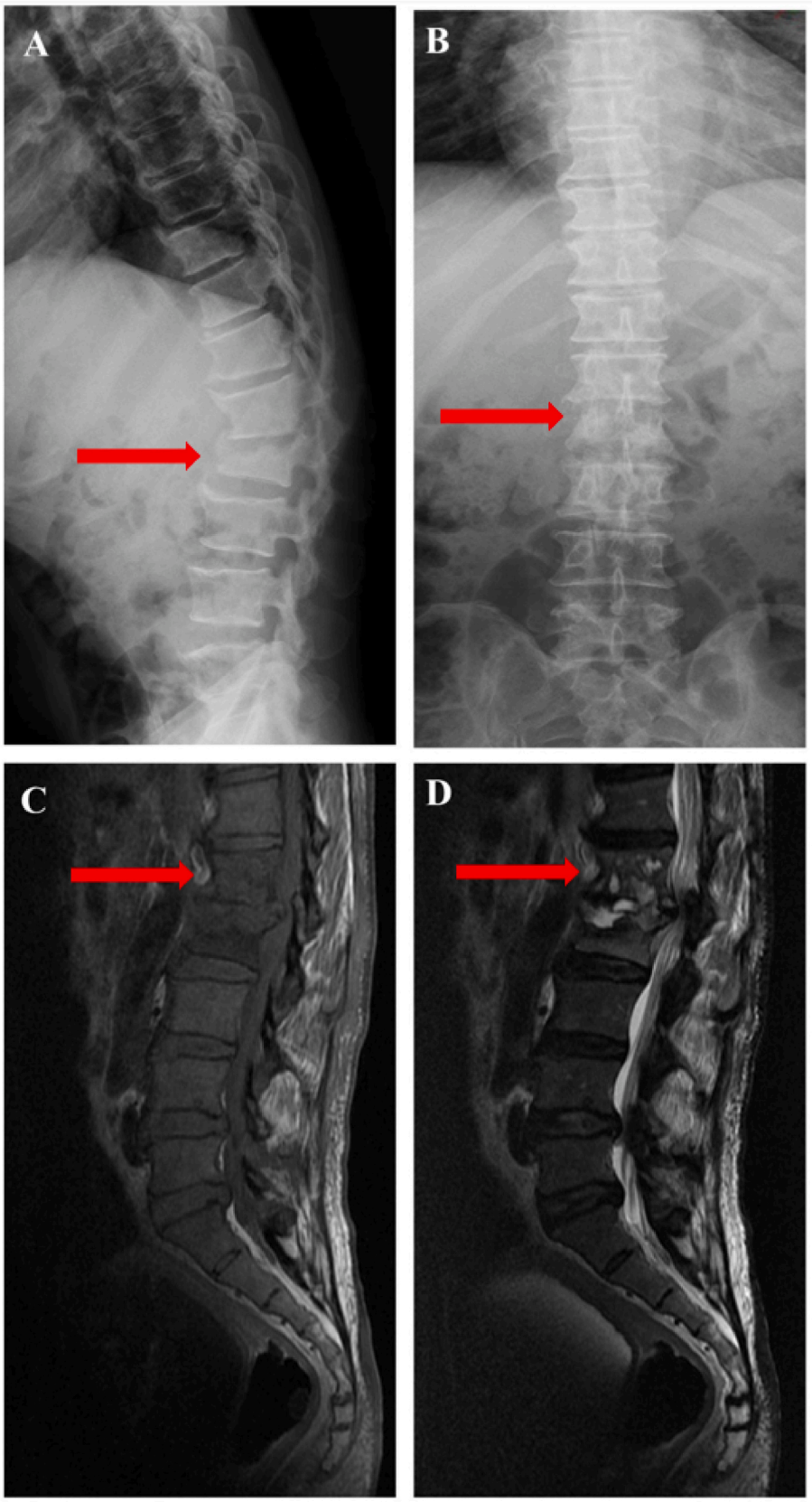

Fig. 1. Radiograph of LS spine [A) Lateral and B) AP] showing the destruction of L1 vertebra with loss of height; C) MRI of LS spine showing the gross destruction of L1 vertebra with marrow changes with D12- L1 end plate changes; and D) MRI of LS spine showing the gross destruction of L1 vertebra with cord compression at the level of D12-L1.

1. Introduction

Brucellosis remains a common zoonotic systemic disease endemic to many developing and developed countries [1–67]. Brucellosis is caused by Brucella melitensis species, an intracellular bacterium [2]. Humans acquire brucellosis through occupational contact in animal husbandry, butcher, and veterinary fields or contaminated dairy products such as milk, cheese, and butter [3–5]. In fact, among the various livestock-related occupational groups, a recent meta-analysis showed that the global pooled prevalence of brucellosis was 14% (95% CI: 10–18), especially in North America and Africa. Indeed, at that meta-analysis, slaughterhouse workers was associated with the highest prevalence (20%; 95% CI: 13–27), affecting particularly workers ages of 20 and 25, which suggests that age also had a role. Therefore, it is concluded that the livestock-related occupational groups were found to be at an increased risk of adverse zoonotic disease outcomes [68].

The predominant clinical findings in human involvement include fever, perspiration, myalgia, lymphadenopathy, or organomegaly [5,6]. The musculoskeletal system is more commonly involved in other systemic presentations [5,7]. Brucellosis is diagnosed mainly by correlation of the physical examination, serological tests, and cultural and imaging methods [6,8]. For a definitive diagnosis of brucellosis, organism isolation from blood or body tissues or by molecular methods remains mandatory [6,8,71].

In brucellosis, osteoarticular involvement is one of the common presentations occurring in 10%–85% of patients with the disease [9,10]. The common osteoarticular manifestations include spondylitis (2%–60%), spondylodiscitis (6%–85%), sacroiliitis (80%), bursitis, osteomyelitis, tenosynovitis and peripheral arthritis (17%) [6,10,11]. This myriad of its presentation makes the patient initially seek the help of general practitioners and finally seek the help of orthopaedic and rheumatology specialists. The variety of clinical manifestations and lack of disease-specific symptomatology is the leading cause of delay in diagnosing osteoarticular brucellosis [12–14].

Brucellosis is endemic in certain parts of India. The prevalence of brucellosis has been widely reported in different states of India, such as Punjab, Orissa, Andhra Pradesh, Rajasthan, Maharashtra, Gujarat, Uttar Pradesh, Goa, and Northern districts of Karnataka [15,16]. The spinal involvement due to brucellosis lead to the most disabling complications. Developing countries like India consider tuberculosis the primary cause of infective spondylodiscitis. Given the increasing number of *Brucella* cases across the country, no literature is presented on the comprehensive management of spinal brucellosis. However, with our experience, we formulated a classification for managing spinal brucellosis.

2. Methods

A single-centred prospective observational study was conducted after getting institutional ethical clearance from September 2018 to September 2020 in our institute in India. We included patients after obtaining informed consent for participation in the study from all age groups with osteoarticular brucellosis, patients with positive *Brucella* agglutination test, patients with blood culture positive for *Brucella,* patients from whom *Brucella* organism isolated from the site of infection. Patients with osteoarticular involvement due to organisms other than *Brucella* and patients who did not continue management in our hospital were excluded from the study. The diagnosis of osteoarticular brucellosis was established by serology, radiological features as shown in Fig. 1, and tissue sampling. The biological materials used to diagnose osteoarticular brucellosis were blood, serum, and local biopsy (if a patient undergoes surgery). Examination of tissue with gram staining ruled out the presence of any other bacterial infections. To conclusively rule out the existence of mycobacterial infections, analysis of tissue with acid-fast bacilli (AFB) staining and GeneXpert® for *Mycobacterium tuberculosis* was also performed in all the cases. Patients with confirmed spinal brucellosis were managed either non-operatively or operatively based on the severity of the presentation.

Table 1
General characteristics of the included patients.

Features	Total (n = 25)	SD
M:F	21:4	
Age	52.16 years	12.53
<35 years	1 (4%)	
36–45 years	6 (24%)	
46–55 years	13 (52%)	
66–75 years	5 (20%)	
Site		
Lumbar	16 (64%)	
Cervical	5 (20%)	
Thoracic	2 (4%)	
Multi-focal spine	1 (4%)	
Others	1 (4%)	
NRS at presentation	6.55	1.66
ESR – Initial	38.53	25.65
CRP – Initial	39.99	39.20
SSC Grade – Initial		
Grade 1	5 (20%)	
Grade 2	12 (48%)	
Grade 3	8 (32%)	

SD, standard deviation. 95%CI, 95% confidence interval. NRS, numerical rating scale.
ESR, erythrocyte sedimentation rate. CRP, c-reactive protein.

Patients diagnosed with spinal brucellosis were initially managed by antibiotic therapy for 10–12 weeks. The medical management given to the study population was an injection of streptomycin 750 mg/1 gm IV or injection of gentamycin 80/160/240 mg IV for 14 days, capsule rifampicin 600 mg oral for 10–12 weeks, and capsule doxycycline 100 mg BD oral for 10–12 weeks duration. The antibiotic dosage was tailored to the patient based on their comorbid profile and weight. Surgically, spinal brucellosis was managed by stabilisation and fusion. The indication for surgical management in our study were progressive neurological deficit, sepsis, patients not responding to medical management, intraspinal empyema, and a prevertebral and paravertebral abscess. The outcome measures were analysed by the degree of radiological involvement, numerical rating scale (NRS) for pain, and spondylodiscitis severity code (SSC) [17]. The SSC at diagnosis of the disease was considered SSC–primary and the SSC reassessed at the end of the 6-month follow-up was considered SSC–follow-up. Response to treatment was assessed with repeat measurements of erythrocyte sedimentation rate (ESR), c-reactive protein (CRP), and *Brucella* agglutination test titers at each follow-up. Radiological outcomes were assessed using radiographs or magnetic resonance imaging (MRI). Features like sclerosis, endplate irregularity, destruction of the vertebra, and instability were evaluated. All patients were followed up at 3, 6, and 12 months per the standard of care with relevant investigations. Clinical improvement in symptoms and return to work were also assessed.

We used IBM® SPSS Version 25 (Chicago, Illinois, USA) for statistical analysis. Continuous variables were presented with mean and standard deviation. Categorical variables were presented in percentages. Analysis of improvement in the continuous variable before and after the treatment with paired student-test and categorical variables with chi-square test. A p-value <0.05 was considered statistically significant.

3. Results

A total of 25 cases were included in the study with spinal brucellosis based on serology, radiology, and tissue sampling in some cases, whose general characteristics are given in Table 1. The mean age of the study participants was 52.16 ± 12.53 years. The majority of them were in 46–55 years (13 patients), followed by 36–45 years (6 patients) and 66–75 years (5 patients). Male preponderance was seen among the study participants with an M: F ratio of 5.25:1. Although *Brucella* can involve any osteoarticular system in the body, the spine's common site of

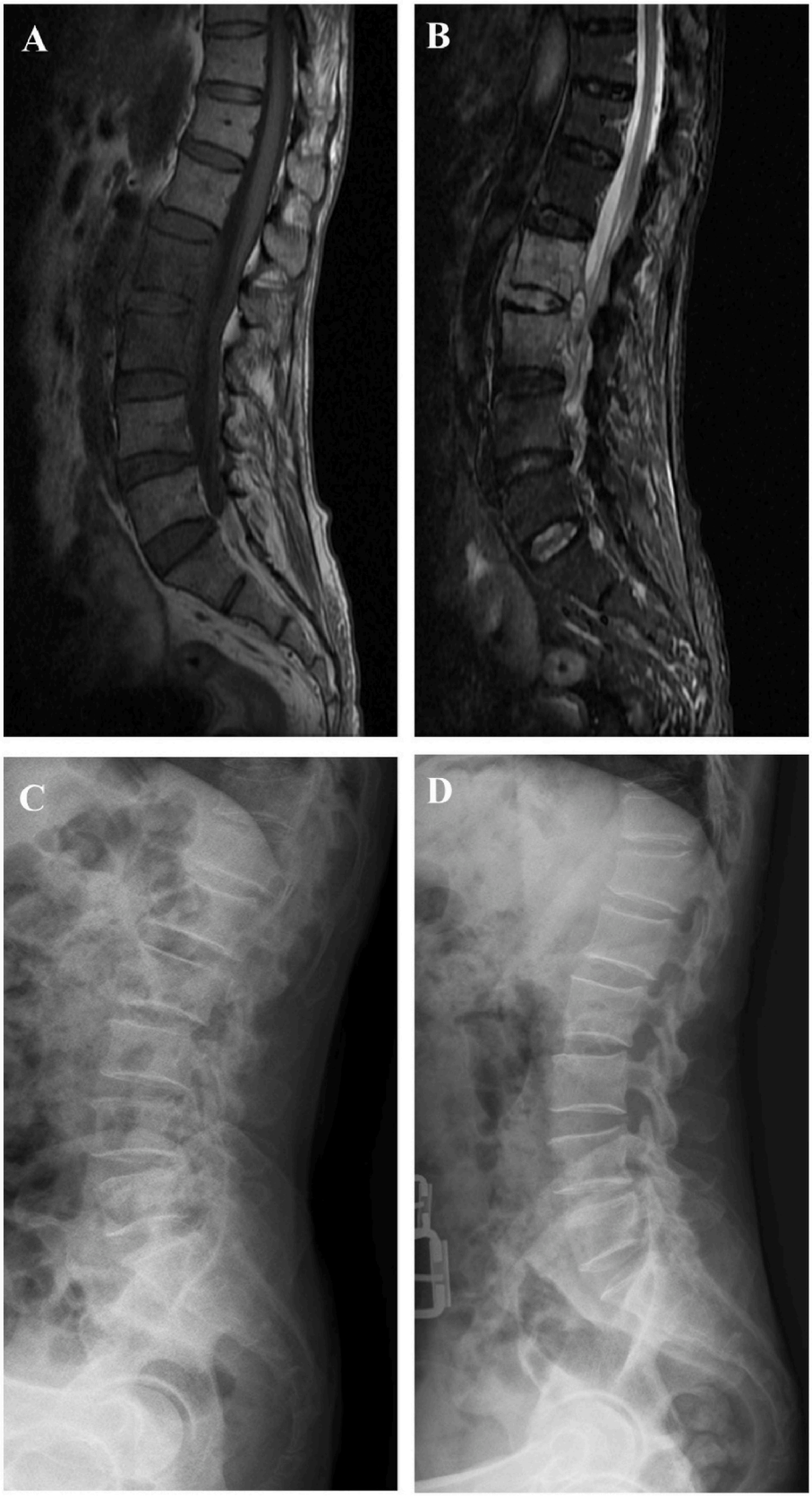

Fig. 2. A, B show T1-W and T2-W preoperative images of L2, L3 spinal brucellosis involving the body and disc space with a collection extending anterior to the spinal body; C, D show the preoperative and postoperative radiographs of the same patient treated conservatively by medical management.

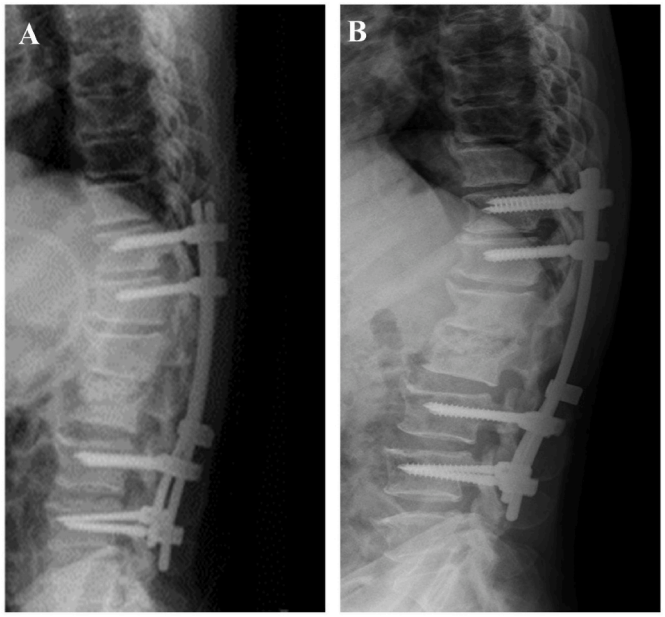

Fig. 3. A, immediate post-op radiograph and B, post-intervention 6th month follow-up radiograph showing dense sclerotic vertebral endplates of L1-L2 vertebra, no collapse of the vertebral body, no loosening of implants.

Table 2
Clinical and serological evaluation of patients.

Variable	Pre (n = 25)	Post (6 months) (n = 25)	Mean difference	95%CI	p-value
NRS	6.55 ± 1.66	2.14 ± 0.96	4.41 ± 1.22	(2.78–5.87)	<0.001
ESR	38.53 ± 25.65	24.35 ± 22.71	14.17 ± 22.05	(2.83–25.51)	0.017
CRP	39.99 ± 39.20	7.78 ± 9.60	32.20 ± 39.98	(11.65–52.76)	0.004

95%CI, 95% confidence interval. NRS, numerical rating scale. ESR, erythrocyte sedimentation rate. CRP, c-reactive protein.

involvement remains. Among the spinal segments, lumbar spondylodiscitis was the most common presentation noted in 16 patients (64%), followed by cervical spondylodiscitis in 5 patients (20%). Other presentations were thoracic spondylodiscitis (8%) and multi-focal spinal lesions (4%).

Patients with regional involvement restricted to dorsal (D11-D12) or lumbar (L2-L3-L4) vertebral segments without any indications for surgery were managed conservatively by antibiotic therapy and rigid brace. Lesions involving the junctional levels with the sign of instability were surgically stabilised along with antibiotic therapy. We noted radiological improvement as a vertebra in the conservatively managed patients with stable sclerosed endplates without ongoing body collapse. Fig. 2 shows that 17 patients were treated exclusively with appropriate antibiotics and brace. Four patients underwent biopsy, and a total of eight patients underwent stabilisation and fusion surgery along with antibiotic therapy without further collapse or deterioration, as shown in Fig. 3. Twelve participants had moderate NRS scoring.

The remaining 13 patients had severe NRS scoring with an overall initial score mean of 6.55 ± 1.66 which improved to 2.14 ± 0.96 ($p < 0.001$) at six months and 2.85 ± 1.24 ($p < 0.001$) at 12 months follow-up respectively both of which were statistically significant compared to the initial score. According to primary SSC grading, five patients belong to grades 1, 12 to grade 2 and 8 to grade 3. At six months of follow-up, 12 patients in grade 2 and 7 in grade 3 reverted to grade 1, except one patient in grade 3 who showed recurrent infection and resorted to grade 2, which improved later. By six month follow-up period, ESR ($p = 0.017$) and CRP ($p = 0.004$) showed a significant reduction compared to initial values, as shown in Table 2. *Brucella* titer value plays an essential role in treatment. The titer value denotes the bacterial load in the blood. Hence even 1/80 titer values with clinical symptoms were started on antibiotic therapy. All patients achieved negative titers that were maintained on serial follow-up except in one patient who presented with recurrence of symptoms at nine months and was diagnosed as having recurrence with positive titers. However, the patient was treated conservatively without any complications. As a result, 88% (n = 22) of the cases showed clinical improvement at six months follow-up, and 68% (n = 17) returned to work by six months. The mean follow-up period was 14.42 ± 8 months.

4. Discussion

Brucellosis remains a significant zoonotic disease in low- and middle-income countries, particularly in the Middle East, the Indian subcontinent, the Mediterranean region, and Latin America [15–67]. Multiple social and environmental aspects still play a significant role in its transmission and against the efforts towards effective control and elimination [15–67]. A the same time, brucellosis is still a significant source of occupational disease, including occupational outbreaks, as recently reported in different countries, such as Brazil and China [69,70].

Brucellosis is endemic in certain parts of India, whereas its prevalence has been widely reported [15,16,21,72,73]. The diagnosis of spinal brucellosis poses a significant challenge among healthcare practitioners. Osteoarticular presentations include spondylitis, sacroiliitis, spondylodiscitis, bursitis, osteomyelitis, tenosynovitis, and peripheral arthritis, representing brucellosis's frequent musculoskeletal manifestation [7,10,22]. *Brucella* spondylitis must be differentiated from tubercular or salmonella or pyogenic spondylitis, disc pathologies, and spinal metastasis [23–26]. Combined clinical and microbiological findings with radiological examination of the spine aid in diagnosing spinal brucellosis.

Spinal brucellosis presents with the preservation of the vertebral architecture, which must be differentiated from spinal tuberculosis as they are India's most common infectious agent [27,28]. Spinal brucellosis affects anterior elements of the spine more than posterior elements [29,30]. The earliest radiological features of spinal brucellosis are non-specific signs such as narrowing of disc space followed by the osteoporosis of the affected vertebra and the erosion of the superior or inferior vertebral body angle (Pons' sign), and hence the diagnosis is often delayed [26,31]. In later stages of spinal brucellosis, focal anterior or diffuse disc collapse, vertebral collapse, and subsequent necrosis and osteomyelitis are seen [30,32]. Advanced modalities like diffusion/perfusion CT, bone scintigraphy, and MRI help detect the extent of spinal brucellosis [24,32,33]. Inflammatory markers like ESR and CRP aid in estimating the follow-up treatment response and prognosis of spinal brucellosis [14,34].

The mean age among our study participants was 52.16 ± 12.53 years. In contrast, in the study by Bosilkovski et al., it was 36 years [35], Hashemi et al. [36] noted 35.47 ± 20.23 years, and Pourbagher et al. [37] noted spinal brucellosis at a mean age of 38 years. The lumbar spine (60%–69%) is the common site of spondylodiscitis in brucellosis [7,38]. Following the literature, we found it the most frequent site [10]. The location of the spine least affected by brucellosis is the cervical spine (6%–12%) [39]. In *Brucella* spondylodiscitis, completely normal findings may be the initial radiographic presentation hampering the early diagnosis of this condition mainly due to the long latency period with spondylodiscitis [40,41].

WHO recommended that the first line for brucellosis is the combination of oral tetracycline with an injectable aminoglycoside [42]. Being bactericidal, fluoroquinolones achieved the maximum concentrations in bone and soft tissues and proved a better outcome in systemic and osteoarticular brucellosis cases. However, due to the increased

Table 3
Management classification for spinal brucellosis.

Severity Grade	Pain	Bone destruction	Adjacent structure involvement	Senosory/Motor deficit	Management
Mild	Does not interfere with work	–	–	–	Antibiotic therapy for 10–12 weeks
Moderate	Interferes with work	+	±	–	Rigid bracing along with antibiotic therapy for 12 weeks
Severe	Excruciating pain that prevents working	±	+	+	Surgical decompression and stabilisation, along with antibiotic therapy for 12 weeks

treatment failure rate and relapse with fluoroquinolones monotherapy, combining fluoroquinolones and tetracyclines is preferred to combat brucellosis [43–45]. The alternate regimen for brucellosis is the combination of oral rifampicin 600 mg/day and oral doxycycline 100 mg twice daily for 4–6 weeks depending upon the disease severity [46–48]. Therefore, we devised our strategy for managing spinal brucellosis, given in Table 3, which is more conservative than the earlier devised treatment plan by Homagk et al. [17].

The duration of antibiotics for brucella spondylitis is longer than systemic brucellosis, along with analgesics and immobilisation for pain relief [42,49,50]. In the case of spinal brucellosis, the duration of the oral rifampicin and oral doxycycline should be continued for more than 2–3 months [9,38,51]. In complicated and severe osteoarticular brucellosis, the treatment regimen must continue for over six months [51]. But still, treatment failure, relapse, and default are reported in the literature. Aygen et al. reported a 12.1% relapse rate in osteoarticular brucellosis with tetracycline and streptomycin group [52]. The patients were incompliant with the toxicities of tetracycline and streptomycin drugs [52]. The data on the triple-drug regimen for osteoarticular and spinal brucellosis are insufficient. A relapse rate of 14% was reported by Solera et al. [50] (doxycycline + gentamicin), 10% by Ariza et al. [53] (tetracycline/doxycycline + co-trimoxazole + streptomycin/rifampicin), 4% by Colmenero et al. [54] (doxycycline + rifampicin or doxycycline + streptomycin), and 55% by Lifeso et al. [55] (tetracycline + streptomycin or co-trimoxazole + rifampicin). We noted a 4% recurrence rate (n = 1) in our series.

The surgical intervention in spinal brucellosis is performed when the patient presents with spinal instability, radiculopathy, cord compression, extradural mass, or cauda equina syndrome [51,56,57]. Out of 11 cases, Nas et al. performed open and micro decompression laminectomies and discectomies in 6 and 2 cases of spinal brucellosis, respectively [51]. Nas et al. insisted on early rehabilitation protocol for spinal brucellosis cases undergoing medical or surgical management. In the acute phase of the disease, isometric exercises are advised, whereas, in the subacute phase, early mobilisation of the patient is recommended [51]. The clinical sequelae in spinal brucellosis are delayed convalescence after treatment [32,58].

Conservative management is the most adopted method of treatment across various studies [44,45,59,60]. The main reason for the success of conservative management is early diagnosis, strict adherence to the antibiotic protocol, and regular follow-up [10,49]. There is no established standard management protocol for osteoarticular brucellosis [32,61]. Streptomycin, rifampicin, doxycycline, other antibiotic combinations, and levamisole were used for the varied duration without any established recommended definitive treatment protocol [42,49,50,58]. In our study, we used the combination of injectable aminoglycosides (streptomycin or gentamycin in varying doses for 14 days) along with oral rifampicin 600 mg BD for 10–12 weeks and oral doxycycline 100 mg BD for 10–12 weeks. The treatment duration was individualised according to the functional need of the patient. The combination treatment was extended to a particular group of patients who needed a long-term successful outcome.

Our study has some limitations. First, the sample size of the patient cohort followed in our study is relatively small. Second, the mean follow-up period was 14.42 ± 8 months; hence long-term follow-up is needed to report on the recurrence rate of the disease in the long run. Third, we concentrated more on the spinal manifestations of the disease in grading the severity. At the same time, the patients may also have other osteoarticular manifestations, which may alter the severity of the disease. However, our treatment classification is more particularly meant for spinal brucellosis. We recommend validating our treatment classification with high-volume studies with sufficient follow-up for widespread acceptance. Finally, our study did not focus on occupational aspects, as well as depending on the organic and functional effects that were manifested, would be interesting to investigate more about the proportion of those who did not improve, and consequently, they were unable, ultimately, to return to work, as well as to define the precise organic cause and/or functional sequelae that prevented them from doing so.

5. Conclusion

A high index of suspicion of patients from endemic regions with proper clinical, serological, and radiological assessment would help in appropriate decision-making (medical/surgical) to manage spinal brucellosis effectively. Serial evaluation with regular follow-up was the key to completing spinal brucellosis treatment. Once spinal brucellosis is confirmed, aggressive antimicrobial therapy with or without surgical management and a comprehensive rehabilitation program must be imposed on patients to prevent further disabilities and deformities.

Funding sources

Universidad Continental grant the costs of APCs of this publication.

CRediT authorship contribution statement

Naveen Jeyaraman: Conceptualization, Investigation, methods, Supervision, analysis, Writing – original draft, writing and review final version. **Madhan Jeyaraman:** Conceptualization, Investigation, methods, Supervision, analysis, Writing – original draft, writing and review final version. **Arulkumar Nallakumarasamy:** Investigation, data collection, analysis, writing and review final version. **Shanmugapriya K:** Investigation, data collection, analysis, writing and review final version. **Suraj Adhikari:** Investigation, data collection, analysis, writing and review final version. **Rishikesh Rijal:** Investigation, data collection, analysis, writing and review final version. **Ankush Asija:** Investigation, data collection, analysis, writing and review final version. **Yub Raj Sedhai:** Investigation, data collection, analysis, writing and review final version. **Sanjit Sah:** Investigation, data collection, analysis, writing and review final version. **Aroop Mohanty:** Investigation, data collection, analysis, writing and review final version. **D. Katterine Bonilla-Aldana:** Investigation, data collection, analysis, writing and review final version. **Ranjit Sah:** Investigation, data collection, analysis, writing and review final version.

Declaration of competing interest

The authors declare that they have no known competing financial interests or personal relationships that could have appeared to influence the work reported in this paper.

References

[1] Gwida M, Al Dahouk S, Melzer F, Rösler U, Neubauer H, Tomaso H. Brucellosis – regionally emerging zoonotic disease? Croat Med J 2010;51(4):289–95. https://doi.org/10.3325/cmj.2010.51.289.

[2] Alton GG, Forsyth JRL. Brucella. In: Baron S, editor. Medical microbiology. fourth ed. University of Texas Medical Branch at Galveston; 1996. http://www.ncbi.nlm.nih.gov/books/NBK8572/. [Accessed 16 May 2021].

[3] Yumuk Z, O'Callaghan D. Brucellosis in Turkey — an overview. Int J Infect Dis 2012;16(4):e228–35. https://doi.org/10.1016/j.ijid.2011.12.011.

[4] Musallam II, Abo-Shehada MN, Guitian J. Knowledge, attitudes, and practices associated with brucellosis in livestock owners in Jordan. Am J Trop Med Hyg 2015;93(6):1148–55. https://doi.org/10.4269/ajtmh.15-0294.

[5] Khurana SK, Sehrawat A, Tiwari R, et al. Bovine brucellosis – a comprehensive review. Vet Q. 41(1):61-88. doi:10.1080/01652176.2020.1868616.

[6] Ulu-Kilic A, Metan G, Alp E. Clinical presentations and diagnosis of brucellosis. Recent Pat Anti-Infect Drug Discov 2013;8(1):34–41.

[7] Hasanjani Roushan MR, Ebrahimpour S, Moulana Z. Different clinical presentations of brucellosis. Jundishapur J Microbiol 2016;9(4):e33765. https://doi.org/10.5812/jjm.33765.

[8] Yagupsky P, Morata P, Colmenero JD. Laboratory diagnosis of human brucellosis. Clin Microbiol Rev 2019;33(1). https://doi.org/10.1128/CMR.00073-19.

[9] Ulu-Kilic A, Karakas A, Erdem H, et al. Update on treatment options for spinal brucellosis. Clin Microbiol Infect 2014;20(2):O75–82. https://doi.org/10.1111/1469-0691.12351.

[10] Esmaeilnejad-Ganji SM, Esmaeilnejad-Ganji SMR. Osteoarticular manifestations of human brucellosis: a review. World J Orthoped 2019;10(2):54–62. https://doi.org/10.5312/wjo.v10.i2.54.

[11] Sanaei Dashti A, Karimi A. Skeletal involvement of *Brucella* melitensis in children: a systematic review. Iran J Med Sci 2013;38(4):286–92.

[12] Bax HI, van Veelen MLC, Gyssens IC, Rietveld AP. Brucellosis, an uncommon and frequently delayed diagnosis. Neth J Med 2007;65(9):352–5.

[13] Madkour MM. Osteoarticular brucellosis. In: Madkour MM, editor. Madkour's brucellosis. Springer; 2001. p. 74–84. https://doi.org/10.1007/978-3-642-59533-2_8.

[14] Unuvar GK, Kilic AU, Doganay M. Current therapeutic strategy in osteoarticular brucellosis. North Clin Istanb 2019;6(4):415–20. https://doi.org/10.14744/nci.2019.05658.

[15] Shome R, Triveni K, Swati S, et al. Spatial seroprevalence of bovine brucellosis in India—a large random sampling survey. Comp Immunol Microbiol Infect Dis 2019;65:124–7. https://doi.org/10.1016/j.cimid.2019.05.002.

[16] Mantur BG, Amarnath SK. Brucellosis in India - a review. J Biosci 2008;33(4):539–47. https://doi.org/10.1007/s12038-008-0072-1.

[17] Homagk L, Homagk N, Klauss JR, Roehl K, Hofmann GO, Marmelstein D. Spondylodiscitis severity code: scoring system for the classification and treatment of non-specific spondylodiscitis. Eur Spine J 2016;25(4):1012–20. https://doi.org/10.1007/s00586-015-3936-8.

[18] Akpinar O. Historical perspective of brucellosis: a microbiological and epidemiological overview. Inf Med 2016;24(1):77–86.

[19] Sofian M, Aghakhani A, Velayati AA, Banifazl M, Eslamifar A, Ramezani A. Risk factors for human brucellosis in Iran: a case–control study. Int J Infect Dis 2008;12(2):157–61. https://doi.org/10.1016/j.ijid.2007.04.019.

[20] Avdikou I, Maipa V, Alamanos Y. Epidemiology of human brucellosis in a defined area of Northwestern Greece. Epidemiol Infect 2005;133(5):905–10. https://doi.org/10.1017/S0950268805003973.

[21] Franc KA, Krecek RC, Häsler BN, Arenas-Gamboa AM. Brucellosis remains a neglected disease in the developing world: a call for interdisciplinary action. BMC Publ Health 2018;18:125. https://doi.org/10.1186/s12889-017-5016-y.

[22] Zheng R, Xie S, Lu X, et al. A systematic review and meta-analysis of epidemiology and clinical manifestations of human brucellosis in China. BioMed Res Int 2018;2018:5712920. https://doi.org/10.1155/2018/5712920.

[23] Lee KY. Comparison of pyogenic spondylitis and tuberculous spondylitis. Asian Spine J 2014;8(2):216–23. https://doi.org/10.4184/asj.2014.8.2.216.

[24] Li T, Li W, Du Y, et al. Discrimination of pyogenic spondylitis from brucellar spondylitis on MRI. Medicine 2018;97(26):e11195. https://doi.org/10.1097/MD.0000000000011195.

[25] Guo H, Lan S, He Y, Tiheiran M, Liu W. Differentiating brucella spondylitis from tuberculous spondylitis by the conventional MRI and MR T2 mapping: a prospective study. Eur J Med Res 2021;26(1):125. https://doi.org/10.1186/s40001-021-00598-4.

[26] Yang B, Hu H, Chen J, He X, Li H. The evaluation of the clinical, laboratory, and radiological findings of 16 cases of *brucellar* spondylitis2016. BioMed Research International; 2016, e8903635. https://doi.org/10.1155/2016/8903635.

[27] Kurtaran B, Sarpel T, Tasova Y, et al. *Brucellar* and tuberculous spondylitis in 87 adult patients: a descriptive and comparative case series. Infect Dis Clin Pract 2008;16(3):166–73. https://doi.org/10.1097/IPC.0b013e318168ffb3.

[28] Gao M, Sun J, Jiang Z, et al. Comparison of tuberculous and *brucellar* spondylitis on magnetic resonance images. Spine 2017;42(2):113–21. https://doi.org/10.1097/BRS.0000000000001697.

[29] Turunc T, Demiroglu YZ, Uncu H, Colakoglu S, Arslan H. A comparative analysis of tuberculous, brucellar and pyogenic spontaneous spondylodiscitis patients. J Infect 2007;55(2):158–63. https://doi.org/10.1016/j.jinf.2007.04.002.

[30] Tali ET. Spinal infections. Eur J Radiol 2004;50(2):120–33. https://doi.org/10.1016/j.ejrad.2003.10.022.

[31] Tuna N, Ogutlu A, Gozdas HT, Karabay O. Pedro pons' sign as a brucellosis complication. Indian J Pathol Microbiol 2011;54(1):183. https://doi.org/10.4103/0377-4929.77398.

[32] Alp E, Doganay M. Current therapeutic strategy in spinal brucellosis. Int J Infect Dis 2008;12(6):573–7. https://doi.org/10.1016/j.ijid.2008.03.014.

[33] Tu L, Liu X, Gu W, et al. Imaging-assisted diagnosis and characteristics of suspected spinal brucellosis: a retrospective study of 72 cases. Med Sci Mon Int Med J Exp Clin Res 2018;24:2647–54. https://doi.org/10.12659/MSM.909288.

[34] Aktar F, Tekin R, Bektaş MS, et al. Diagnostic role of inflammatory markers in pediatric *Brucella* arthritis. Ital J Pediatr 2016;42(1):3. https://doi.org/10.1186/s13052-016-0211-5.

[35] Bosilkovski M, Krteva L, Caparoska S, Dimzova M. Osteoarticular involvement in brucellosis: study of 196 cases in the Republic of Macedonia. Croat Med J 2004;45(6):727–33.

[36] Hashemi SH, Keramat F, Ranjbar M, Mamani M, Farzam A, Jamal-Omidi S. Osteoarticular complications of brucellosis in Hamedan, an endemic area in the west of Iran. Int J Infect Dis 2007;11(6):496–500. https://doi.org/10.1016/j.ijid.2007.01.008.

[37] Pourbagher A, Pourbagher MA, Savas L, et al. Epidemiologic, clinical, and imaging findings in brucellosis patients with osteoarticular involvement. AJR Am J Roentgenol 2006;187(4):873–80. https://doi.org/10.2214/AJR.05.1088.

[38] Koubaa M, Maaloul I, Marrakchi C, et al. Spinal brucellosis in South of Tunisia: review of 32 cases. Spine J 2014;14(8):1538–44. https://doi.org/10.1016/j.spinee.2013.09.027.

[39] Chelli Bouaziz M, Ladeb MF, Chakroun M, Chaabane S. Spinal brucellosis: a review. Skeletal Radiol 2008;37(9):785–90. https://doi.org/10.1007/s00256-007-0371-x.

[40] Bozgeyik Z, Ozdemir H, Demirdag K, Ozden M, Sonmezgoz F, Ozgocmen S. Clinical and MRI findings of brucellar spondylodiscitis. Eur J Radiol 2008;67(1):153–8. https://doi.org/10.1016/j.ejrad.2007.07.002.

[41] Oztekin O, Calli C, Adibelli Z, Kitis O, Eren C, Altinok T. *Brucellar* spondylodiscitis: magnetic resonance imaging features with conventional sequences and diffusion-weighted imaging. Radiol Med 2010;115(5):794–803. https://doi.org/10.1007/s11547-010-0530-3.

[42] Alavi SM, Alavi L. Treatment of brucellosis: a systematic review of studies in recent twenty years. Caspian J Intern Med 2013;4(2):636–41.

[43] Skalsky K, Yahav D, Bishara J, Pitlik S, Leibovici L, Paul M. Treatment of human brucellosis: systematic review and meta-analysis of randomised controlled trials. BMJ 2008;336(7646):701–4. https://doi.org/10.1136/bmj.39497.500903.25.

[44] Ariza J, Bosilkovski M, Cascio A, et al. Perspectives for the treatment of brucellosis in the 21st century: the ioannina recommendations. PLoS Med 2007;4(12):e317. https://doi.org/10.1371/journal.pmed.0040317.

[45] Ranjbar M. Treatment of brucellosis. IntechOpen; 2015. https://doi.org/10.5772/61093.

[46] CDC. Home - Brucellosis. 2021. https://www.cdc.gov/brucellosis/index.html. [Accessed 25 November 2021].

[47] Brucellosis. NORD (national organization for rare disorders). https://rarediseases.org/rare-diseases/brucellosis/. [Accessed 28 November 2021].

[48] WHO. Brucellosis. https://www.who.int/news-room/fact-sheets/detail/brucellosis. [Accessed 28 November 2021].

[49] Yousefi-Nooraie R, Mortaz-Hejri S, Mehrani M, Sadeghipour P. Antibiotics for treating human brucellosis. Cochrane Database Syst Rev 2012;2012(10). https://doi.org/10.1002/14651858.CD007179.pub2.

[50] Solera J, Espinosa A, Martínez-Alfaro E, et al. Treatment of human brucellosis with doxycycline and gentamicin. Antimicrob Agents Chemother 1997;41(1):80–4. https://doi.org/10.1128/AAC.41.1.80.

[51] Nas K, Gür A, Kemaloğlu MS, et al. Management of spinal brucellosis and outcome of rehabilitation. Spinal Cord 2001;39(4):223–7. https://doi.org/10.1038/sj.sc.3101145.

[52] Aygen B, Doğanay M, Sümerkan B, Yildiz O, Kayabaş Ü. Clinical manifestations, complications and treatment of brucellosis: a retrospective evaluation of 480 patients. Med Maladies Infect 2002;32(9):485–93. https://doi.org/10.1016/S0399-077X(02)00403-1.

[53] Ariza J, Gudiol F, Valverde J, et al. *Brucellar* spondylitis: a detailed analysis based on current findings. Rev Infect Dis 1985;7(5):656–64. https://doi.org/10.1093/clinids/7.5.656.

[54] Colmenero J, Jimenez-Mejias M, Sanchez-Lora F, et al. Pyogenic, tuberculous, and brucellar vertebral osteomyelitis: a descriptive and comparative study of 219 cases. Ann Rheum Dis 1997;56(12):709–15.

[55] Lifeso RM, Harder E, McCorkell SJ. Spinal brucellosis. J Bone Joint Surg Br 1985;67(3):345–51. https://doi.org/10.1302/0301-620X.67B3.3997939.

[56] Yin Z, He E, Ding H, Chen J. *Brucella* infection of the thoracic vertebral arch presenting with an epidural abscess: a case report. J Med Case Rep 2015;9:237. https://doi.org/10.1186/s13256-015-0713-6.

[57] Katonis P, Tzermiadianos M, Gikas A, Papagelopoulos P, Hadjipavlou A. Surgical treatment of spinal brucellosis. Clin Orthop Relat Res 2006;444:66–72. https://doi.org/10.1097/01.blo.0000203455.59393.9a.

[58] Alp E, Koc RK, Durak AC, et al. Doxycycline plus streptomycin versus ciprofloxacin plus rifampicin in spinal brucellosis [ISRCTN31053647]. BMC Infect Dis 2006;6(1):72. https://doi.org/10.1186/1471-2334-6-72.

[59] Falagas ME, Bliziotis IA. Quinolones for treatment of human brucellosis: critical review of the evidence from microbiological and clinical studies. Antimicrob Agents Chemother 2006;50(1):22–33. https://doi.org/10.1128/AAC.50.1.22-33.2006.

[60] Al-Tawfiq JA. Therapeutic options for human brucellosis. Expert Rev Anti Infect Ther 2008;6(1):109–20. https://doi.org/10.1586/14787210.6.1.109.

[61] Mermut G, Özgenç O, Avcı M, et al. Clinical, diagnostic and therapeutic approaches to complications of brucellosis: an experience of 12 years. MPP (Major Probl Pathol) 2012;21(1):46–50. https://doi.org/10.1159/000331588.
[62] Bosilkovski M, Rodriguez-Morales AJ. Brucellosis and its particularities in children travelers. Recent Pat Anti-Infect Drug Discov 2014;9(3):164–72. https://doi.org/10.2174/1574891x10666150408162624. PMID: 25851430.
[63] Rodríguez-Morales AJ. Climate change, climate variability and brucellosis. Recent Pat Anti-Infect Drug Discov 2013 Apr;8(1):4–12. https://doi.org/10.2174/1574891x11308010003. PMID: 22873353.
[64] Oral H, Sönmezer MÇ, Yıldız AE, Hazırolan G, Metan G, İnkaya AÇ. Disseminated *Brucella* melitensis infection following canakinumab treatment. Trav Med Infect Dis 2022 Jan-Feb;45:102227. https://doi.org/10.1016/j.tmaid.2021.102227. Epub 2021 Nov 29. PMID: 34856407.
[65] Lewis JM, Folb J, Kalra S, Squire SB, Taegtmeyer M, Beeching NJ. *Brucella* melitensis prosthetic joint infection in a traveller returning to the UK from Thailand: case report and review of the literature. Trav Med Infect Dis 2016 Sep-Oct;14(5):444–50. https://doi.org/10.1016/j.tmaid.2016.08.010. Epub 2016 Aug 31. PMID: 27591088; PMCID: PMC5093331.
[66] Hosseini SM, Farmany A, Abbasalipourkabir R, Soleimani Asl S, Nourian A, Arabestani MR. Doxycycline-encapsulated solid lipid nanoparticles for the enhanced antibacterial potential to treat the chronic brucellosis and preventing its relapse: in vivo study. Ann Clin Microbiol Antimicrob 2019 Nov 9;18(1):33. https://doi.org/10.1186/s12941-019-0333-x. PMID: 31706304; PMCID: PMC6842259.
[67] Cascio A, Bosilkovski M, Rodriguez-Morales AJ, Pappas G. The socio-ecology of zoonotic infections. Clin Microbiol Infect 2011 Mar;17(3):336–42. https://doi.org/10.1111/j.1469-0691.2010.03451.x. PMID: 21175957.
[68] Mia MM, Hasan M, Pory FS. Occupational exposure to livestock and risk of tuberculosis and brucellosis: a systematic review and meta-analysis. One Health 2022 Sep 6;15:100432. https://doi.org/10.1016/j.onehlt.2022.100432. PMID: 36277098; PMCID: PMC9582573.
[69] Zhang Z, Tong Y, Lei X, Liu L, Deng Z, Sun F, Ma H, Chang Z, Zhang L, Liu H, Chen Q, Zheng J, Chen H, Sun X, Wu Y, Guan X. First outbreak of occupational brucellosis involving multiple clusters - hubei province, China, 2019. China CDC Wkly 2020 Sep 25;2(39):757–60. https://doi.org/10.46234/ccdcw2020.119. PMID: 34594755; PMCID: PMC8393011.
[70] Zhang Z, Tong Y, Lei X, Liu L, Deng Z, Sun F, Ma H, Chang Z, Zhang L, Liu H, Chen Q, Zheng J, Chen H, Sun X, Wu Y, Guan X. First outbreak of occupational brucellosis involving multiple clusters - hubei province, China, 2019. China CDC Wkly 2020 Sep 25;2(39):757–60. https://doi.org/10.46234/ccdcw2020.119. PMID: 34594755; PMCID: PMC8393011.
[71] Alton GG, Forsyth JRL. Brucella. In: Baron S, editor. Medical microbiology. fourth ed. University of Texas Medical Branch at Galveston; 1996. http://www.ncbi.nlm.nih.gov/books/NBK8572/. [Accessed 16 May 2021].
[72] Jia B, Zhang F, Lu Y, Zhang W, Li J, Zhang Y, Ding J. The clinical features of 590 patients with brucellosis in Xinjiang, China with the emphasis on the treatment of complications. PLoS Neglected Trop Dis 2017 May 1;11(5):e0005577. https://doi.org/10.1371/journal.pntd.0005577. PMID: 28459811; PMCID: PMC5426775.
[73] Luan H, Liu K, Deng X, Sheng W, Mamat M, Guo H, Li H, Deng Q. One-stage posterior surgery combined with anti-Brucella therapy in the management of lumbosacral brucellosis spondylitis: a retrospective study. BMC Surg 2022 Nov 18;22(1):394. https://doi.org/10.1186/s12893-022-01847-x. PMID: 36401260; PMCID: PMC9673312.