

Journal Pre-proof

Isolated intramuscular Cysticercosis with a pseudo Volkmann's sign


Madhan Jeyaraman, Sathish Muthu

PII: S2773-157X(22)00008-X

DOI: <https://doi.org/10.1016/j.jorep.2022.03.008>

Reference: JOREP 8

To appear in: *Journal of Orthopaedic Reports*



Please cite this article as: Jeyaraman M, Muthu S, Isolated intramuscular Cysticercosis with a pseudo Volkmann's sign, *Journal of Orthopaedic Reports*, <https://doi.org/10.1016/j.jorep.2022.03.008>.

This is a PDF file of an article that has undergone enhancements after acceptance, such as the addition of a cover page and metadata, and formatting for readability, but it is not yet the definitive version of record. This version will undergo additional copyediting, typesetting and review before it is published in its final form, but we are providing this version to give early visibility of the article. Please note that, during the production process, errors may be discovered which could affect the content, and all legal disclaimers that apply to the journal pertain.

© 2022 The Author(s). Published by Elsevier B.V. on behalf of Prof. PK Surendran Memorial Education Foundation.

Isolated intramuscular Cysticercosis with a pseudo Volkmann's sign

Madhan Jeyaraman¹, Sathish Muthu²

¹Department of Orthopaedics, Faculty of Medicine, Sri Lalithambigai Medical College and Hospital, Dr MGR Educational and Research Institute, Chennai, Tamil Nadu, India

²Department of Orthopaedics, Government Medical College and Hospital, Dindigul, Tamil Nadu, India

Address for the correspondence

Dr.Sathish Muthu, Department of Orthopaedics, Government Medical College and Hospital, Dindigul, Tamil Nadu, India. E-mail ID – drsathishmuthu@gmail.com

Isolated intramuscular Cysticercosis with a pseudo Volkmann's sign

Keywords: Intramuscular; Cysticercosis; Pseudo Volkmann's sign; Flexor digitorum profundus

Description

A 34-year-old male, presented with pain and swelling in the right forearm and inability to straighten middle and ring fingers of right hand (Fig. 1), for the last 15 days. He gave a history of similar swelling thrice in the same location with an interval of four months of each episode. The patient was on an irregular frequency of medications. Clinically, he had a pseudo Volkmann's sign. Plain radiographs revealed soft tissue shadow of the proximal 1/3rd of the right forearm (Fig. 2A) and ultrasonography (USG) revealed an isolated Cysticercosis of the proximal 1/3rd of the forearm (Fig. 2B). He was oral Albendazole (400 mg twice daily) and Praziquantel (600 mg thrice daily) for six weeks. At the end of this therapy, a USG revealed a regression of the lesion, and specs of calcification were observed at the proximal 1/3rd of the right flexor digitorum profundus muscle (Fig. 3A). Clinically, there was the disappearance of pseudo Volkmann's sign (Fig. 3B).

Centre for Disease Control and Prevention (CDC) Working Group on Parasitic Diseases declared that Cysticercosis is a potentially eradicable disease.¹ It has remained a major public health problem due to the ingestion of undercooked pork infected with cysticerci or contaminated vegetables contaminated by *Taeniasolium*eggs.² The clinical manifestations depend upon the involved organ (muscle, heart, brain, eye, lung, liver, and subcutaneous tissue). Isolated intramuscular cysticerci is an extremely rare occurrence, and it may present as a mass (pseudotumor or abscess), myalgia, and pseudohypertrophy type.³ Our

case presented with a pseudotumor type of intramuscular Cysticercosis with a pseudo Volkmann's sign.

The differential diagnosis for isolated intramuscular Cysticercosis includes lipoma, intramuscular abscess, cold abscess, fibroma, hemangioma, neurofibroma, epidermoid cyst, hydatid cyst, and myositis.³ The plain radiographs show a soft tissue swelling and calcified cyst walls whereas high-resolution ultrasound depicts the presence of cyst with an echogenic scolex as shown in Fig.2B.⁴ The live cyst which appears as hyperintense Cysticercosis lesion and hypointense scolex within the cyst can be demonstrated with MRI.⁴ Among serological testing, enzyme-linked immune-electro-transfer blot (EITB) assay [94 to 98% sensitivity and 100% specificity] is more accurate in detecting Cysticercosis than enzyme-linked immunosorbent assay (ELISA) [65% sensitivity and 63% specificity].² When the parasite is alive within the cyst, anticysticercal drugs like Praziquantel and Albendazole are used to curb off Cysticercosis. If a calcified cyst is observed, surgical excision has to be performed. In our case, the disappearance of pseudo Volkmann's sign was observed after six weeks of medical management. Lifestyle modification, environmental and sanitary improvement, disease education, and antihelminthic drugs can reduce the Cysticercosis burden in the community.⁵

Figure legends

Fig. 1 : Swelling in the proximal 1/3rd of the right forearm (marked area) and the pseudo-Volkmann's sign in the right middle and ring fingers.

Fig. 2A : Plain radiograph with soft tissue swelling in the proximal 1/3rd of the right forearm and Fig. 2B showing USG with the appearance of scolex and surrounding soft tissue edema measuring 1.03 cm x 0.84 cm in the flexor digitorum profundus muscle.

Fig. 3A: An ultrasonography scan revealing specs of calcification at proximal 1/3rd of right flexor digitorum profundus muscle

Fig. 3B : Disappearance of pseudo Volkmann's sign clinically.

Take home message

- Cysticercosis is a potentially eradicable disease.
- The mimicking conditions must be excluded to reach a diagnosis.
- Lifestyle modification, environmental and sanitary improvement, disease education, and antihelminthic drugs can reduce the Cysticercosis burden in the community.

Acknowledgements: Nil

Funding sources: Nil

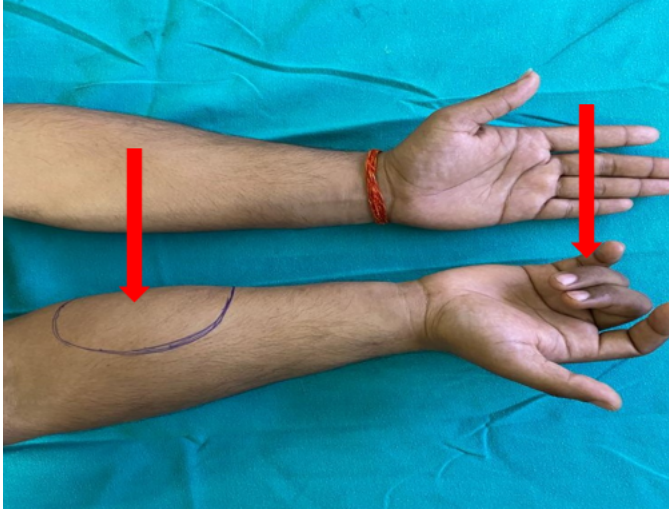
Conflicts of interest: Nil

Consent: An informed consent was taken from the patient

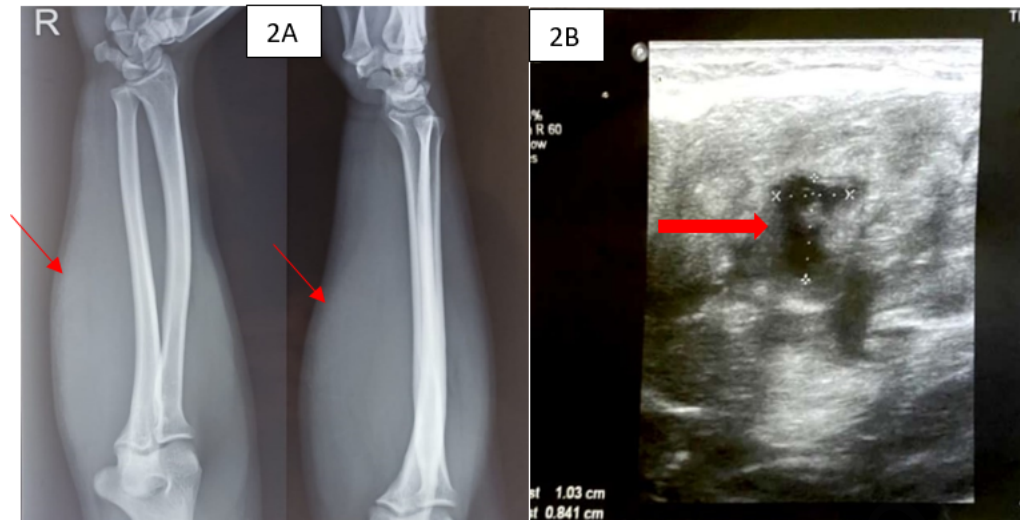
References

1. Report of the Workgroup on Parasitic Diseases. Accessed January 18, 2022. <https://www.cdc.gov/mmwr/preview/mmwrhtml/su48a21.htm>
2. Agarwal S, Akhtar MN. Cysticercosis of Extensor Carpi Ulnaris - A differential diagnosis for painful swelling at elbow. *J Orthop Case Rep.* 2011;1(1):3-6.
3. Kanhere S, Bhagat M, Phadke V, George R. Isolated Intramuscular Cysticercosis: A Case Report. *Malays J Med Sci MJMS.* 2015;22(2):65-68.

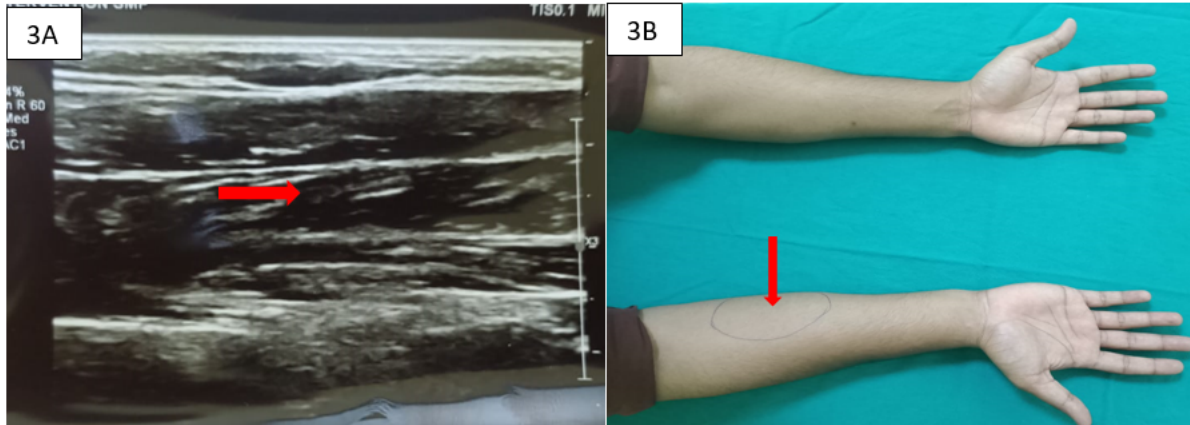
4. Jankharia BG, Chavhan GB, Krishnan P, Jankharia B. MRI and ultrasound in solitary muscular and soft tissue cysticercosis. *Skeletal Radiol.* 2005;34(11):722-726. doi:10.1007/s00256-005-0954-3
5. Meena D, Gupta M, Jain VK, Arya RK. Isolated intramuscular cysticercosis: Clinicopathological features, diagnosis and management – A review. *J Clin Orthop Trauma.* 2016;7(Suppl 2):243-249. doi:10.1016/j.jcot.2016.06.016



Journal Pre-proof



Journal Pre-proof



Journal Pre-proof