Case Report | Journal of Orthopaedic Case Reports 2025 May:15(5):Page 136-140

Talus with Trimalleolar Fracture: A Three-planar Injury of Ankle Joint Complex: A Unique Case Report

Santanu Kar[1], A S Pon Aravindhan[2], Ritvik Janardhanan[2], Nitish Jagdish Jyoti[2], Vijay Sharma[2], Madhan Jeyaraman[3]

Learning Point of the Article:

Talus fractures with associated trimalleolar injuries require management through open reduction and internal fixation. Close monitoring for instability and avascular necrosis is essential, and surgical arthrodesis may be necessary at a later stage if complications arise.

Abstract

Introduction: Malleolar fractures are common, often bimalleolar/trimalleolar. Talus fractures are rare, with risks like avascular necrosis (AVN). Unique challenges arise, especially in combined injuries, sometimes needing ankle arthrodesis.

Case Report: An 18-year-old male laborer presented with a history of fall from height and sustained injury over the right ankle. Imaging showed a talar body fracture with a trimalleolar fracture on the same ankle. After the subsidence of swelling at 9 days, the patient underwent open reduction and internal fixation using screws and plates for malleolar fracture and Herbert screw for talus fracture. At 1-year follow-up, the patient had adequate range of motion of the ankle which was painless without any signs of AVN. The patient underwent ankle arthrodesis at 5 years old as he developed severe pain in the joint. After 1 year of arthrodesis, the patient has pain-free motion of the ankle joint.

Conclusion: Such fractures are rare with a unique mechanism of injury. There are chances of arthritis and instability owing to the variable cartilage damage and occult ligament injury. Stress radiographs after fracture union can help predict ankle instability. Internal fixation is the method of treatment in the acute setting, though the chances of late arthritis are high.

Keywords: Trimalleolar, avascular necrosis, instability, arthrodesis.

Introduction

Malleolar fractures are common injuries presenting to orthopedic trauma emergencies, and in most scenarios, these present as bimalleolar or trimalleolar fractures usually affecting young patients [1]. On the other hand, talus fractures are of lower incidence accounting for far <1% of all fractures [1]. Isolated malleolar fractures have a predictable outcome [2]. Talar injuries present a wide variety of unique treatment challenges with a profound impact on the long-term functional outcomes for the patient due to their association with avascular necrosis (AVN) or post-traumatic arthritis [3]. Talar fractures with associated medial malleolar fractures can save the talar body from AVN due to the preservation of the deltoid branches of the talus [3].

Talus with malleolar fractures has been occasionally reported in the literature [2-4]. Talar body sagittal comminution with a trimalleolar fracture is an extremely rare injury that is always associated with some degree of articular cartilage damage at the time of index injury that leads to ankle arthritis over a few years [5,6]. Moreover, there can be associated ligament injuries around the ankle that destabilize the joint even after optimal

Access this article online

Website: www.jocr.co.in

DOI: https://doi.org/10.13107/jocr.2025.v15.i05.5586

Author's Photo Gallery


Dr. Santanu Kar


Dr. A S Pon Aravindhan


Dr. Ritvik Janardhanan


Dr. Nitish Jagdish Jyoti


Dr. Vijay Sharma


Dr. Madhan Jeyaraman

[1]Department of Orthopaedics, Subham Hospitals, Cooch Behar, West Bengal, India,
[2]Department of Orthopaedics, All India Institute of Medical Sciences, New Delhi, India,
[3]Department of Orthopaedics, ACS Medical College and Hospital, Dr MGR Educational and Research Institute, Chennai, Tamil Nadu, India.

Address of Correspondence:
Dr. A S Pon Aravindhan,
Department of Orthopaedics, All India Institute of Medical Sciences, New Delhi, India.
E-mail: madhan.ponra@gmail.com

Submitted: 20/02/2025; Review: 12/03/2025; Accepted: April 2025; Published: May 2025

DOI: https://doi.org/10.13107/jocr.2025.v15.i05.5586

© The Author(s). 2025 Open Access. This article is distributed under the terms of the Creative Commons Attribution 4.0 International License (https://creativecommons.org/licenses/by-nc/4.0/), which permits unrestricted use, distribution, and non-commercial reproduction in any medium, provided you give appropriate credit to the original author(s) and the source, provide a link to the Creative Commons license, and indicate if changes were made. The Creative Commons Public Domain Dedication waiver (http://creativecommons.org/publicdomain/zero/1.0/) applies to the data made available in this article, unless otherwise stated.



Figure 1: Pre-operative radiographs in an anteroposterior and lateral view showing a fracture of the talus with a trimalleolar fracture.



Figure 2: Sagittal cuts of computed tomography scan showing a fracture of the talar body and posterior malleolar fracture.

fixation [7]. Here, we report a case with closed trimalleolar ankle fracture with sagittal comminuted talar body fracture that had a short-term favorable result, but evidence of radiographic subluxation and ankle pain later necessitated ankle arthrodesis after 2 years. To the best of our knowledge, only one such case has been reported to date but that was an open fracture with a laceration of the posterior tibial tendon [8].

Case Report

An 18-year-old male laborer fell from 10 feet height while working and sustained an injury over his right ankle. He presented to our emergency department with a grossly swollen, painful, and deformed right ankle and foot without any neurovascular deficit. The skin was intact, with ecchymoses over the dorsum of the foot. A subsequent radiograph performed after initial resuscitation demonstrated a trimalleolar fracture with a talar body fracture on the right side (Fig. 1). The fracture was initially managed with analgesics, ankle splint with limb elevation, and cold fomentation. A computed tomography scan was performed to delineate the fracture morphology, which demonstrated a comminuted talar body fracture (81B 3.3) with partial uncovering of the distal tibial articular surface and posterior migration of the posterior fragment of the talus. The posterior malleolar fragment was displaced as well as rotated concerning the tibial plafond. The medial and lateral malleolar fragments were minimally displaced (Fig. 2-4).

The patient was planned for open reduction with internal fixation after the subsidence of swelling 9 days after injury. Anticipating the nature of severe soft-tissue damage minimal invasive surgery was performed. The posterior and lateral malleoli were fixed with the posterolateral approach. At first, the lateral malleolus was anatomically fixed with a one-third tubular plate followed by the posterior malleolus with one 4.5 mm

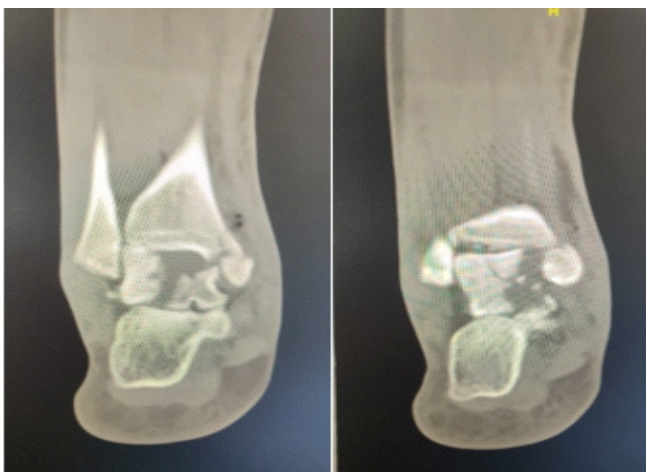

Figure 3: Coronal computed tomography scan cuts showing a talar fracture with fracture of the medial and lateral malleolus.

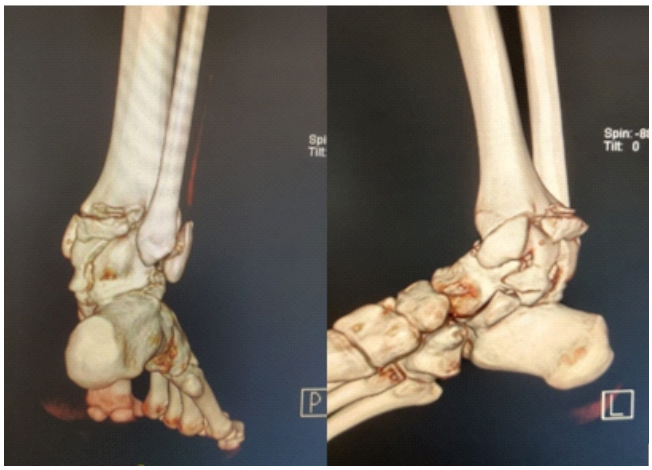

Figure 4: 3D reconstruction of the computed tomography scan showing the fracture morphology.

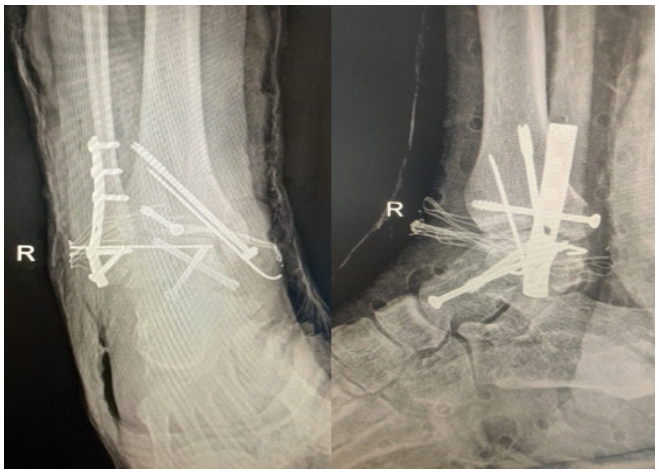

Figure 5: Immediate post-operative radiographs of the talus with trimalleolar fracture.

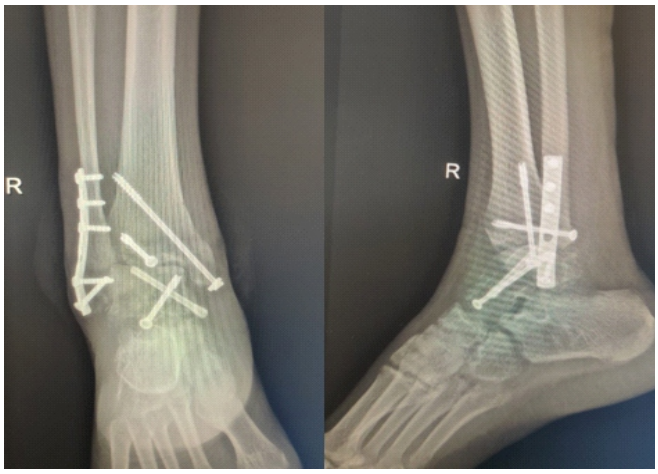

Figure 6: Post-operative radiographs at 6-week follow-up after removal of K-wires.

cannulated cancellous screw. After that, the comminuted talar body fracture was approached from the medial side through the fracture site of the medial malleolus, and reduction was held with K-wire. The reduction was confirmed under an image intensifier and an anteromedial and anterolateral Herbert screw and cannulated cancellous screws (CCSs) were used for fixation. Then, the medial malleoli were provisionally fixed with 2 K-wires. Definitive fixation of the medial malleolus was performed with a 4.5 mm CCS. One K-wire at the medial malleolus and another K-wire that was used for provisional fixation of the tibial plafond from the lateral to the medial side were retained. The joint congruity was checked and found to be satisfactory (Fig. 5). A below-knee back slab was applied for 4 weeks, and the patient was advised non-weight-bearing mobilization. At 6 weeks, the K-wires were removed (Fig. 6). The radiological union was evident at 16 weeks, and the patient was allowed to bear weight at about 6 months after surgery. The patient was mobilized with pain-free range of motion (ROM) at the final follow-up. At 1-year follow-up, dorsiflexion at the right ankle was 15° and plantar flexion was 25°. There was no sign of AVN of the talus at 18 months of follow-up (Fig. 7). Minimal joint space narrowing was present, but the talus appeared laterally displaced. At 5-year follow-up, the patient experienced severe pain in the ankle and underwent ankle arthrodesis. At a 7-year follow-up after ankle arthrodesis, the patient had a pain-free ankle joint.

Discussion

Closed trimalleolar ankle fractures combined with a comminuted sagittal talar body fracture are rarely reported. One case of open trimalleolar with talar neck fracture associated with posterior tibial tendon injury has been reported previously [8]. The rarity of the combination fracture type is due to the unique mechanism of injury that caused such an unusual fracture pattern. The patient had a history of fall from about 10 feet height on an uneven surface. The axial force resulting from this fall would lead to a calcaneum fracture usually. However, there was no injury to the calcaneum in this case. We think that the fall was not directly on the calcaneum but rather on the midfoot region (as the surface was not even, the hindfoot did not receive the primary impact but was caught in a trough on the land) that caused sudden severe dorsiflexion with impingement of talar neck with the anterior tibial plafond. This impingement with tangential impact force fractured the talar body and posterior malleolus. After landing on the ground, subsequent axial compression with internal rotation caused the failure of the lateral malleolus in tension and medial malleolus in compression. We think that the combination of rotational and axial force on the midfoot is the causative factor for such an injury, which is not seen in everyday scenarios. At 18-month follow-up, we noted that there was a mild lateral shifting of the talus which suggested the ankle was not stable. This might have been due to occult intrasubstance injuries to the deltoid ligament which might have occurred after such a devastating injury. After the patient returned to pre-injury functional status, the injured ligament could have been stretched out and resulted in ankle instability. We think that after fracture union, stress radiographs should be done to rule out these occult ligament injuries. We thought that a single screw supplemented with K-wires was sufficient for medial malleolus fixation. However, retrospectively, we presume that another 4 mm CCS for medial malleolus fixation would have been better to prevent rotational malalignment of the medial malleolus.

AVN, or osteonecrosis, is the most common complication following displaced fractures of the talus due to interruption of the blood supply to the sinus tarsi and the tarsal tunnel [4] and



Figure 7: 18-month follow-up radiographs of ankle arthrodesis for ankle instability.

its incidence is high, especially when the talar neck and body fractures are combined. The risk is lower when talar body fractures are combined with malleolar fractures since soft-tissue attachments to the talar body fragment remain. Medial malleolus fracture along with talar body fracture in the sagittal plane is a blessing in disguise as literature has shown that it may preserve some blood supply through its intact deltoid ligament branches of the posterior tibial artery to the talar body. Hence, the risk of AVN of the talus is less in associated medial malleolar fractures. We assume that we did not encounter AVN of talus in our case due to this reason. Isolated talar body fractures generally have poorer outcomes compared to neck fractures. While neck fractures are considered extra-articular, affecting only the middle facet of the subtalar joint, body fractures are intra-articular, involving both the tibiotalar and subtalar joints. [9, 10]. Anatomic and stable reduction of talar body fractures is of utmost importance for obtaining a reasonable functional outcome. Post-traumatic wound dehiscence, AVN of the talus, and ankle arthritis are usual complications seen following such fractures. These types of injuries are always considered severe which can cause variable damage to articular cartilage. In this case, we also noted ankle arthritis after 5 years that necessitated ankle fusion after implant removal. The patient's functional score was satisfactory with a good ROM. We should keep in mind that these fractures are slow to unite; hence, we should use a below-knee cast for a longer time and non-weight-bearing mobilization to be followed till the fracture unites with frequent follow-up at regular intervals. Most of the previous studies have advised non-weight-bearing for a minimum of 6–8 weeks and have reported good clinical outcomes on subsequent follow-up.

Our suggested protocol to approach such injuries is as follows: Assess initial wound and skin condition properly and delay definitive intervention till the skin becomes amenable for surgery. This period can be managed with temporary external stabilization and cold fomentation with limb elevation and active movements. Surgery can be done under regional anesthesia. Malleoli other than medial malleolus shall be fixed first on a lateral approach. This should be followed by talar fixation making use of the available medial malleolus osteotomy. The final fixation of the medial malleolus will complete the fixation. Patients have to be kept non-weight-bearing till radiological union.

Conclusion

Closed talus with a trimalleolar fracture is rare with a unique mechanism of injury. Although the incidence of AVN is lower, the chance of arthritis and instability can be there due to variable cartilage damage and occult ligament injury. Stress radiographs after fracture union can be helpful to predict ankle instability.

Clinical Message

- Talus fractures with associated trimalleolar injuries require management through open reduction and internal fixation.
- Close monitoring for instability and AVN is essential, and surgical arthrodesis may be necessary at a later stage if complications arise.

Declaration of patient consent: The authors certify that they have obtained all appropriate patient consent forms. In the form, the patient has given the consent for his/ her images and other clinical information to be reported in the journal. The patient understands that his/ her names and initials will not be published and due efforts will be made to conceal their identity, but anonymity cannot be guaranteed.

Conflict of interest: Nil **Source of support:** None

References

1. Weatherall J, Schwarzkopf R. Combined ankle and talus fractures--a case report. Bull Hosp Jt Dis (2013) 2013;71:161-5.

2. Arkesh M, Gaba S, Das S, Palanisamy JV, Trikha V. A rare combination of sagittal plane fracture of talar body with medial malleolus fracture: Case report and review of literature. J Clin Orthop Trauma 2016;7:30-4.

3. Mechchat A, Bensaad S, Shimi M, Elibrahimi A, Elmrini A. Unusual ankle fracture: A case report and literature review. J Clin Orthop Trauma 2014;5:103-6.

4. Radaideh AM, Audat ZA, Saleh AA. Talar neck fracture with dislocation combined with bimalleolar ankle fracture: A case report. Am J Case Rep 2018;19:320-4.

5. Thangarajah T, Bishnoi A, Thangarajah S, Espag MP. An unusual ankle injury. JRSM Short Rep. 2011 Mar 21;2(3):19.

6. Vallier HA, Nork SE, Benirschke SK, Sangeorzan BJ. Surgical treatment of talar body fractures. J Bone Joint Surg Am 2003;85-A:1716-24.

7. Sneppen O, Christensen SB, Krogsøe O, Lorentzen J. Fracture of the body of the talus. Acta Orthop 1977;48:317-24.

8. Burton PD, Page BJ 2nd. Fracture of the neck of the talus associated with a trimalleolar ankle fracture and ruptured tibialis posterior tendon. J Orthop Trauma 1992;6:248-51.

9. Caracchini G, Pietragalla M, De Renzis A, Galluzzo M, Carbone M, Zappia M, et al. Talar fractures: Radiological and CT evaluation and classification systems. Acta Biomed 2018;89:151-65.

10. Shakked RJ, Tejwani NC. Surgical treatment of talus fractures. Orthop Clin North Am 2013;44:521-8.

Conflict of Interest: Nil
Source of Support: Nil

Consent: The authors confirm that informed consent was obtained from the patient for publication of this case report

How to Cite this Article

Kar S, Aravindhan ASP, Janardhanan R, Jyoti NJ, Sharma V, Jeyaraman M. Talus with Trimalleolar Fracture: A Three-planar Injury of Ankle Joint Complex: A Unique Case Report. Journal of Orthopaedic Case Reports 2025 May;15(5):136-140.