An update to this article is included at the end

Journal of Orthopaedic Reports 1 (2022) 100053

Contents lists available at ScienceDirect

Journal of Orthopaedic Reports

journal homepage: www.journals.elsevier.com/journal-of-orthopaedic-reports

Clinical Images

Alveolar Rhabdomyosarcoma of Spine in an adult masquerading as Pott's spine

Madhan Jeyaraman [a,*], Naveen Jeyaraman [b]

[a] Department of Orthopaedics, Faculty of Medicine, Sri Lalithambigai Medical College and Hospital, Dr MGR Educational and Research Institute, Chennai, Tamil Nadu, India
[b] Department of Orthopaedics, Atlas Hospitals, Tiruchirappalli, Tamil Nadu, India

ARTICLE INFO

Keywords:
Alveolar rhabdomyosarcoma
Tuberculosis
Iliopsoas abscess

ABSTRACT

Introduction: Rhabdomyosarcoma (RMS) is a soft tissue tumor arising from myogenic precursor cells. RMS involving the spine primarily is rare, with only few such reported cases.
Clinical image report: A 43 year old gentleman had complains of low back pain, weakness of lower limbs and urinary incontinence for three months. With radiological and histopathological investigations, the patient was diagnosed as alveolar type of RMS.
Conclusion: Identifying the histological type of RMS pave a way for the treatment plan and to prognosticate the disease activity.

1. Description

A 43 year old gentleman had complains of low back pain, weakness of lower limbs and urinary incontinence for three months. He was bed ridden for the past one month. He had no previous medical conditions. On examination, he was found to have diffuse tenderness over the lumbar spine. Fixed flexion deformity of the hips was present. Gross weakness of bilateral lower limbs was noted. Sensations were intact. All lower limb reflexes were absent and patient was noted to have an autonomous bladder. Blood investigations showed elevated inflammatory markers. Radiographs of the spine only showed a loss of lumbar lordosis. Magnetic Resonance Imaging (MRI) of the spine showed a hypointense lesion involving the L3-L4 region. Heterogeneous involvement of the L3 and L4 vertebral bodies, maintained vertebral height, partial destruction of L3-L4 intervertebral disc, abnormal signal intensity of the corresponding region of spinal cord, and a paravertebral soft tissue mass were noted as shown in Fig. 1. Based on these findings, an orthopaedic surgeon at another hospital had diagnosed the patient to have Pott's spine. He was started on anti-tuberculosis treatment (ATT). However despite ATT for one month, the patient's condition had further deteriorated. We performed a Positron Emission Tomography (PET) scan, which revealed a metabolically active large paravertebral mass in the lumbosacral region involving the iliopsoas and erector spinae muscles as shown in Fig. 2. Focal involvement of L3–L5 vertebra, neural foramina and extension into the spinal canal was also present as shown in Fig. 2. A Fine Needle Aspiration Cytology (FNAC) of the lesion showed features characteristic of Rhabdomyosarcoma (RMS). Focally solid arrangement of tumour cells with central loss of cohesion in alveolar spaces and necrosis, suggested it to be an alveolar variant of RMS as shown in Fig. 3. Chemo-radiotherapy was planned to be initiated, however the patient's condition deteriorated rapidly and the patient succumbed to the disease.

Rhabdomyosarcoma is a soft tissue tumor arising from myogenic precursor cells, occurring predominantly in the first decade of life.[1] They are aggressive tumors, leading to poor long term survival rate. They occur very rarely in adults, and have shown poorer prognosis than in children.[2] Primary RMS usually involves the head, neck, urogenital system or extremities. RMS involving the spine primarily is rare, with only few such reported cases.[3] RMS occurring in an adult, and presenting with complaints mimicking a local spinal infection has not been reported earlier. In our case, the age of the patient, MRI finding of involvement of one disc, adjacent vertebrae and presence of soft tissue shadow was suggestive of Pott's spine. However, the soft tissue mass appeared more solid, suggestive of a malignancy, rather than having a cystic appearance suggestive of a tuberculous abscess. The PET scan finding of activity along iliopsoas, is a possible finding in iliopsoas abscess, commonly associated with tuberculosis of the spine. It was only a histopathological examination which proved the diagnosis of RMS. The histology was characteristic of a rare variant of RMS called Alveolar RMS. It is important to identify

* Corresponding author.
E-mail address: madhanjeyaraman@gmail.com (M. Jeyaraman).

https://doi.org/10.1016/j.jorep.2022.100053
Received 21 June 2022; Accepted 25 June 2022
Available online 30 June 2022
2773-157X/© 2022 The Author(s). Published by Elsevier B.V. on behalf of Prof. PK Surendran Memorial Education Foundation. This is an open access article under the CC BY-NC-ND license (http://creativecommons.org/licenses/by-nc-nd/4.0/).

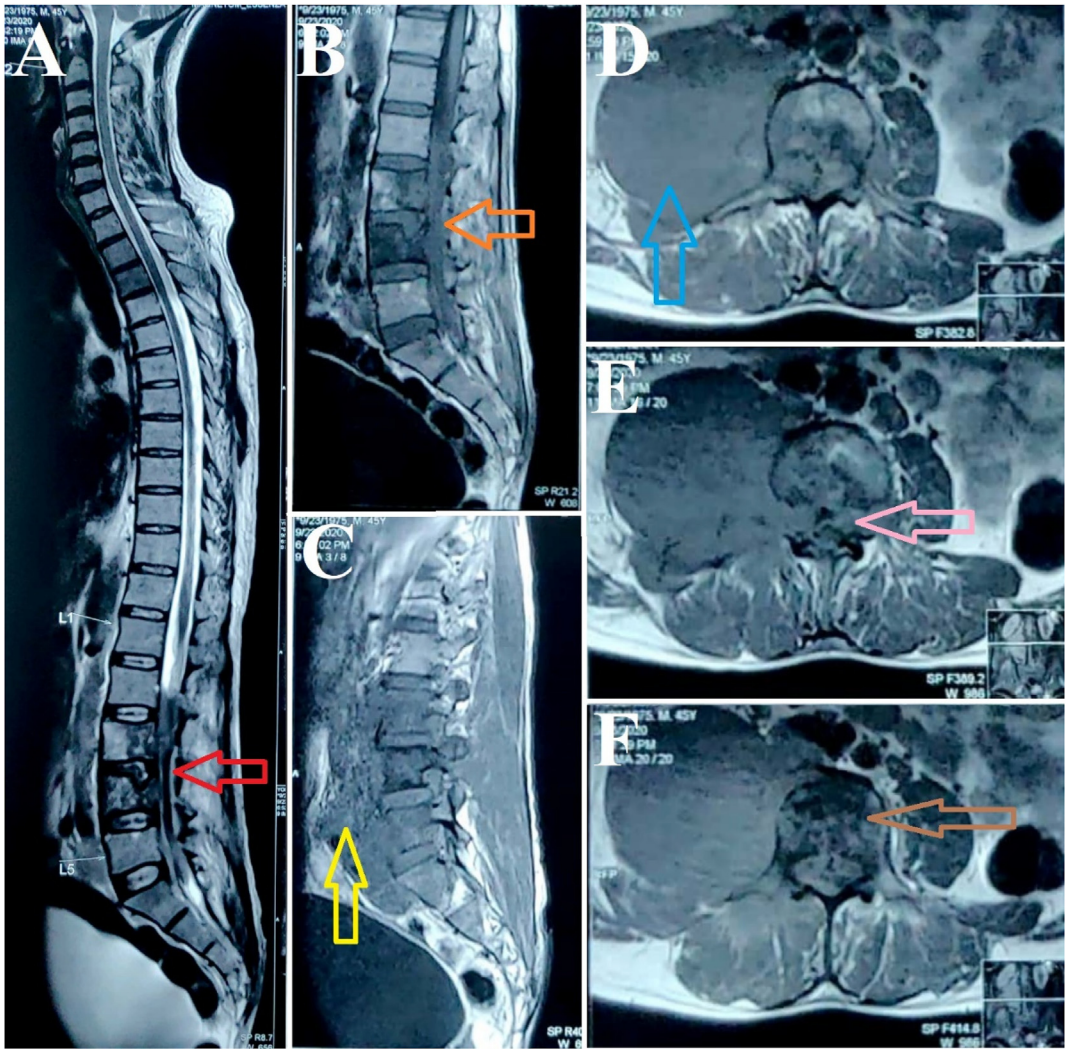

Fig. 1. MRI of the spine. (A) T2 sagittal section showing hypointense lesion involving the L3-L4 vertebral region (red arrow). Heterogeneous involvement of L3-L4 vertebrae, partial destruction of L3-L4 vertebral disc, and involvement of adjacent spinal cord noted. (B) T1 sagittal section showing lesion to be hypointense (orange arrow). (C) Large soft tissue mass (yellow arrow) seen anterior to vertebral column. (D) Axial section showing large paravertebral soft tissue mass (blue arrow). (E) The mass is seen involving the spinal cord (pink arrow) and extending to contralateral side. (F) Heterogeneous destruction of vertebral body noted (brown arrow). (For interpretation of the references to colour in this figure legend, the reader is referred to the Web version of this article.)

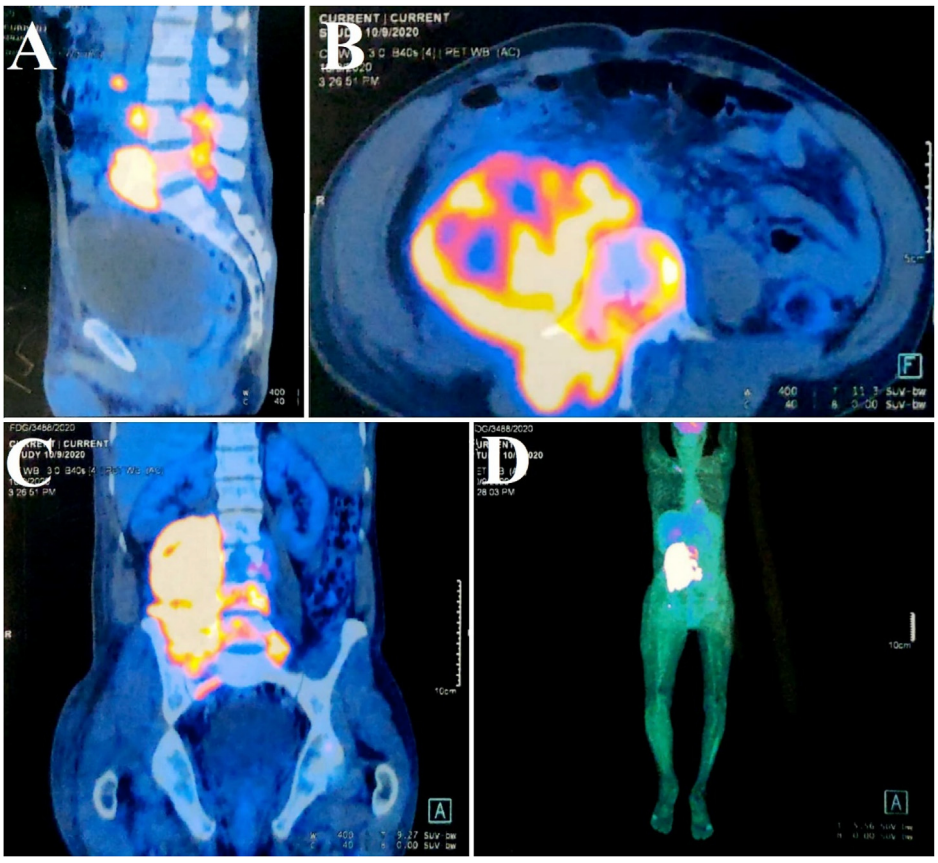

Fig. 2. PET scan. (A, B) Increased activity noted in lumbosacral region, involving L4-L5 vertebral, spinal cord and paravertebral soft tissue. (C) Increased activity along right iliopsoas muscle. (D) Focal enhancement of mediastinal lymph nodes noted.

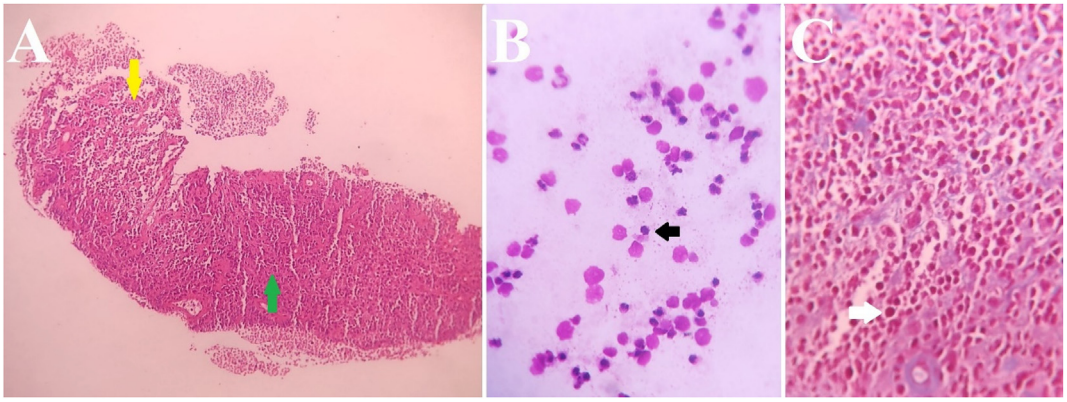

Fig. 3. Histopathological analysis of FNAC of the lesion. (A) Extensive round to oval tumor cells. Solid arrangement of densely packed cells (green arrow) separated by fibrous septa. Alveolar arrangement of tumour cells (yellow arrow) with central loss of cohesion in alveolar spaces. (B) Tumor cells (black arrow) showing pleomorphism, high Nuclear-Cytoplasmic radio, prominent nucleoli, with few multilobed forms. Background shows inflammatory infiltrate. (C) Tumor cells seen to stain red with Masson Trichome stain, suggestive of muscular differentiation. (For interpretation of the references to colour in this figure legend, the reader is referred to the Web version of this article.)

the histological type of RMS as alveolar RMS has been shown to be more aggressive and have worse prognosis than other histological variants of RMS.[4]

Take home message

- Rhabdomyosarcoma may rarely occur in adults
- Rhabdomyosarcoma involving the spine may mimic Pott's spine clinically and on imaging.
- It is important to identify the histological variant of RMS as Alveolar RMS is more aggressive and has worse prognosis.

Informed consent

An informed consent was obtained from the patient for this publication.

Declaration of patient consent form

Patient declares no conflict of interest in publishing the case report for academic purposes.

Institutional ethical committee approval

Not required.

Funding sources

Nil.

Author contributions

All authors have contributed equally in writing the manuscript. All authors have read and agreed to the published version of the manuscript.

Declaration of competing interest

Nil.

Acknowledgements

Nil.

References

1. Dasgupta R, Fuchs J, Rodeberg D. Rhabdomyosarcoma. *Semin Pediatr Surg*. 2016;25:276–283.
2. Esnaola NF, Rubin BP, Baldini EH, et al. Response to chemotherapy and predictors of survival in adult rhabdomyosarcoma. *Ann Surg*. 2001;234:215–223.
3. Wang T, Gao X, Yang J, et al. Treatment strategies and outcomes for spinal rhabdomyosarcoma: a series of 11 cases in a single center and review of the literature. *Clin Neurol Neurosurg*. 2020;192, 105729.
4. Dziuba I, Kurzawa P, Dopierała M, et al. Rhabdomyosarcoma in children - current pathologic and molecular classification. *Pol J Pathol*. 2018;69:20–32.

Update

Journal of Orthopaedic Reports

Volume 1, Issue 3, September 2022, Page

DOI: https://doi.org/10.1016/j.jorep.2022.100081

Journal of Orthopaedic Reports 1 (2022) 100081

Contents lists available at ScienceDirect

Journal of Orthopaedic Reports

journal homepage: www.journals.elsevier.com/journal-of-orthopaedic-reports

Corrigendum

Corrigendum to "Alveolar Rhabdomyosarcoma of Spine in an adult masquerading as Pott's spine" [J. Orthop. Rep. 1(3) (2022) 100053]

Madhan Jeyaraman [a,*], Naveen Jeyaraman [b]

[a] Department of Orthopaedics, Faculty of Medicine – Sri Lalithambigai Medical College and Hospital, Dr MGR Educational and Research Institute, Tamil Nadu, India
[b] Department of Orthopaedics, Atlas Hospitals, Tiruchirappalli, Tamil Nadu, India

The authors regret that the author names have been missed and below is the correct order of authors.

The authors would like to apologise for any inconvenience caused.

1)Dr VK Gautam

Professor of Orthopaedics SMS&R, Sharda University greater Noida.

2)Dr JADAV AZAD

PG RESIDENT

SMS&R, Sharda University greater Noida.

3)Dr RAHUL KAUL

ASSOCIATE PROFESSOR SMS&R, Sharda University greater Noida.

4)Madhan Jeyraman

Department of Orthopaedics, Faculty of Medicine, Sri Lalithambigai Medical College and Hospital, Dr MGR Educational and Research Institute, Chennai, Tamil Nadu, India

Naveen Jeyaraman

Department of Orthopaedics, Atlas Hospitals, Tiruchirappalli, Tamil Nadu, India

DOI of original article: https://doi.org/10.1016/j.jorep.2022.100053.

* Corresponding author.
E-mail address: madhanjeyaraman@gmail.com (M. Jeyaraman).

https://doi.org/10.1016/j.jorep.2022.100081

Available online 24 September 2022

2773-157X/© 2022 The Author(s). Published by Elsevier B.V. on behalf of Prof. PK Surendran Memorial Education Foundation. This is an open access article under the CC BY-NC-ND license (http://creativecommons.org/licenses/by-nc-nd/4.0/).