Journal of Orthopaedic Reports 1 (2022) 100054

Contents lists available at ScienceDirect

Journal of Orthopaedic Reports

journal homepage: www.journals.elsevier.com/journal-of-orthopaedic-reports

Case Report

Non-traumatic simultaneous bilateral neck of femur fracture in a 9-year old child: A case report and review of literature

Nishant D. Goyal [a], Nikhil Valsangkar [a], Shekhar Shrivastav [a], Madhan Jeyaraman [b,*]

[a] Department of Orthopaedics, Sant Parmanand Hospital and Delhi Institute of Trauma and Orthopaedics, New Delhi, India
[b] Department of Orthopaedics, Faculty of Medicine - Sri Lalithambigai Medical College and Hospital, Dr MGR Educational and Research Institute, Chennai, 600095, Tamil Nadu, India

ARTICLE INFO

Keywords:
Non-traumatic
Seizures
Hypocalcemia
Vitamin D

ABSTRACT

Introduction: Non-traumatic simultaneous bilateral neck of femur fracture after hypocalcemic seizures, especially in a child less than 10 years of age is underreported in literature.
Case presentation: A 9-year female child presented to us with simultaneous non-traumatic fractures of the bilateral neck femur following the first episode of seizures which was caused due to hypocalcemia resulting from primary nutritional vitamin D deficiency. Closed reduction and internal fixation with cannulated cancellous screws were done for both the fractures in the same sitting after optimizing the metabolic abnormality.
Conclusion: An underlying metabolic cause should always be looked for in simultaneous bilateral fractures of the neck of the femur. Treatment should be prompt and rehabilitation slow, along with correction of the metabolic abnormality. A multidisciplinary approach helps to prevent associated future consequences.

1. Introduction

Occurrence of simultaneous bilateral neck of femur fracture without a history of significant trauma in the pediatric population is extremely rare to encounter. Simultaneous bilateral fractures have been reported in connection with metabolic diseases like renal osteodystrophy, osteoporosis, or after electroconvulsive therapy or after significant trauma.[1,2] Bilateral fractures of the humerus and femur and fracture-dislocations of the shoulder and hip are recognized to occur in epileptic fits.[3] All the cases of bilateral fracture occurring due to various etiologies without a history of significant trauma have been reported in the adult population.[4,5] The literature is scanty about the Pediatric simultaneous bilateral neck of femur fracture after seizures. Only two such cases have been reported in the literature but those are in the adolescent population.[6,7] Hence, we report this unique case.

2. Case report

A 9-year female child presented with bilateral hip pain and inability to bear weight after a seizure episode. She developed the first episode of seizures suddenly about an hour ago while playing at home. The seizure episode lasted for 3–4 minutes which was witnessed by her mother and described as rhythmic shaking movements of all extremities and backward rolling of the eyes. The child has not sustained any external injury during the seizure episode. Following seizures, she started complaining of excruciating pain in both hips and was unable to walk.

3. Clinical findings

At presentation, the child was afebrile with stable vitals except for the VAS pain scale which was 7/10. She was moderately built with moderate obesity (BMI - 31.2) without any evidence of deformity. She has examined for her bilateral hip pain which revealed contracted quadriceps bilaterally and exquisite pain on palpation of both thighs. The pain prevented her from sitting or walking. She had a generalized increase in muscle tone. There was no previous history of hypocalcemia given by the mother. Deep tendon reflexes were diminished. Chvostek and Trousseau's signs were positive suggesting the possibility of hypocalcemia.

4. Diagnostic assessment

The radiograph of pelvis with bilateral hips AP view revealed bilateral Delbet type 2 neck of femur fracture as shown in Fig. 1. The bilateral neck of femur fracture without any significant history of trauma aroused the suspicion of metabolic or pathological fracture. On detailed evaluation, it was found that the child was homebound with poor dietary habits.

* Corresponding author.
E-mail address: madhanjeyaraman@gmail.com (M. Jeyaraman).

https://doi.org/10.1016/j.jorep.2022.100054
Received 24 May 2022; Received in revised form 23 June 2022; Accepted 27 June 2022
Available online 3 July 2022
2773-157X/© 2022 The Author(s). Published by Elsevier B.V. on behalf of Prof. PK Surendran Memorial Education Foundation. This is an open access article under the CC BY-NC-ND license (http://creativecommons.org/licenses/by-nc-nd/4.0/).



Fig. 1. Plain radiograph of pelvis with bilateral hips showing Bilateral Delbet type 2 Neck of femur fracture.

Considering the unusual nature of fracture without significant trauma, a metabolic blood profile was obtained and the observed values were as follows.

a. Serum calcium - 4.5 mg/dL (Reference range- 8.7–10 mg/dL).
b. Alkaline phosphatase-338 U/L (reference range: 33–96 U/L),
c. Parathyroid hormone 515 pg/mL (reference range: 8–51 pg/mL),
d. Vitamin D 1,25-dihydroxy level −4 pg/mL (reference range: 15–75 pg/mL).

No evidence of hypoglycemia, dyselectrolytemia, and hypomagnesemia was found. CT brain and EEG were within normal limits. With the above metabolic disturbances, the diagnosis of primary nutritional Vitamin D3 deficiency leading to rickets with secondary hyperparathyroidism was made. The workup for malabsorption syndromes was normal.

4.1. Therapeutic intervention

The serum calcium was normalized over 24 hours using intravenous calcium gluconate (10%), and seizure pharmaco-prophylaxis was initiated.

4.2. Details of surgical intervention

She was taken up for surgery the next day. Bilateral hip closed reduction was done with gentle, sustained traction applied in line with the femoral neck, with the hip flexed and externally rotated to untwist and relax the spiral fibers of the hip capsule. Followed by internal rotation, gradual extension, and abduction to maintain the reduction. The bilateral leg was put on a traction table with maintained reduction and the right hip followed by the left hip operated on under the guidance of an image intensifier. Intra-articular decompression was not done in any hip. Internal fixation was done using two 6.5-mm cannulated cancellous screws in each hip. The anatomical reduction was achieved for both the hips with good purchase in the femoral head and neck as shown in Fig. 2. As it was a stable fixation, there was no need to further immobilize with the hip spica. Post-operatively, the patient was given an IV antibiotic for 1 day along with analgesics, and anti-inflammatory medication for 2 days, followed by oral antibiotics for 7 days. As serum calcium was normalized before, post-operatively patient was given oral calcium 500 mg + Vitamin D3 400 IU till discharge.

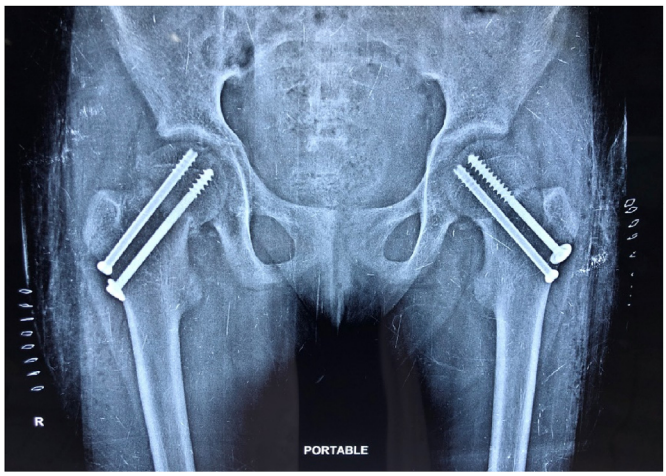

Fig. 2. Immediate post–op radiograph showing bilateral neck of femur fracture fixed with canulated cancellous screws.

4.3. Follow-up and outcome

Following discharge, the patient was advised to take seizure prophylaxis and calcium–vitamin D supplementation (oral calcium 500 mg + Vitamins D3 400 IU one tablet twice daily for 3 months). Serum Vitamin D3 levels were already normalized using intravenous calcium gluconate, hence only a maintenance dose was required, as advised by an endocrinologist. The patient was regularly followed up every month for the first 3 months. The patient was on non-weight bearing for 3 months and was advised for regular follow-up with the physiotherapist for passive range exercises for both hips and isometric quadriceps exercises. At the end of 3 months, the metabolic profile turned out to be normal. Pain-free range of motion of both hips and the union of bilateral neck of femur fracture union were noted at 3 months and progressive weight-bearing was started. No recurrent seizures were observed during the entire postoperative and follow-up period. At 1-year follow-up, X-ray showed complete union of bilateral neck of femur fracture as shown in Fig. 3. The patient was ambulating independently and was able to sit cross-leg comfortably and squat without any pain or difficulty as shown in Fig. 4. Based on clinical examination and x-ray findings it was clear that there was no occurrence of avascular necrosis, in this case, hence no additional investigation was advised.

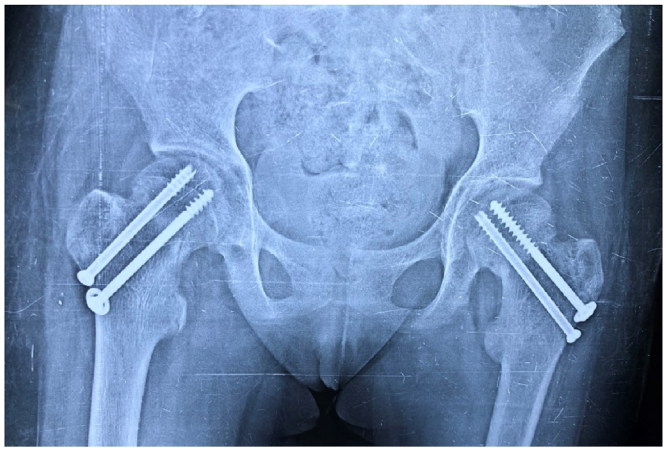

Fig. 3. 1-year follow up radiograph showing completely united neck of femur fracture on both sides with canulated cancellous screws in-situ.



Fig. 4. Clinical images showing full range of movements of bilateral hips at last follow up.

5. Discussion

Femoral neck fractures secondary to metabolic causes or deficiencies are rare and few cases have been published. Vitamin D deficiency is highly prevalent in growing children due to the increased metabolic demands as a result of rapid growth, poor vitamin D or calcium intake, changing food habits like junk foods with increased phosphorous content, decreased physical activity, sedentary lifestyle, and diminished exposure to sunlight or malabsorption syndromes.[8] Most children with Vitamin D deficiency are asymptomatic and seemingly unnoticed, under-investigated and under-reported in the literature. However, when symptomatic, they tend to present with signs of hypocalcemia and rarely seizures.

Narchi et al. reported 21 cases of symptomatic vitamin D deficiency in adolescents with carpopedal spasm, limb pain, or weakness and without seizures[9] whereas Ladhani et al. reported 16 cases of symptomatic vitamin D deficiency presented with seizures.[10] There were only two case reports of hypocalcemia-induced seizures in children.[6,7] Vestergaard et al. reported that the patients with epilepsy are twice as likely to sustain a fracture as patients without epilepsy, which may be a result of increased risk of trauma, and decreased bone density due to the usage of the antiepileptic drug, and/or comorbidities.[11] A few case reports described that femoral fractures caused by the muscular tension due to a seizure episode seem to be unusual.[12,13]

In our case, the child was previously asymptomatic, was not on any medication, and sustained the first episode of seizure followed by excruciating pain over the bilateral hip which was diagnosed as bilateral femoral neck fracture without a traumatic etiology. Metabolic and neoplastic causes are searched for any fracture that happened without significant trauma, especially after an episode of seizures. The differential diagnosis of hypocalcemia in adolescence includes vitamin D deficiency, hypoparathyroidism, hypomagnesemia, malabsorption, and renal and hepatic failure.[14] The diagnosis of primary vitamin D deficiency causing hypocalcemia is made when low vitamin D levels are accompanied by high levels of PTH, in the absence of other metabolic or gastrointestinal abnormalities. Once hypocalcemia is found, additional laboratory investigations such as obtaining a basic metabolic panel, liver function tests, and PTH and vitamin D 25-hydroxy and 1,25-dihydroxy levels should be performed. A workup for malabsorption should be undertaken if it is suggested by history or initial laboratory results.

Based on laboratory investigation, it was likely that his vitamin D deficiency was nutritional. Hypocalcemic seizures should be treated with intravenous calcium and magnesium should be replaced if low levels are identified. Once the underlying cause of the seizure has been treated, fractures requiring surgical fixation should be fixed with appropriate implants. To ascertain the cause of bilateral neck of femur fracture without significant trauma, we concluded that violent and sudden contraction of the proximal femoral musculature coupled with the subclinical weakening of the bone caused due to low vitamin D levels and hypocalcemia was the underlying mechanism of injury in our case.

6. Conclusion

Emergency medicine physicians should carefully evaluate patients with seizures for secondary injuries, both at presentation and after the patient recovers from the postictal stage. In bilateral femoral neck fractures, especially after seizures, it is advisable to look for underlying metabolic disturbances which may cause bone weakening. Correction of the metabolic profile ensures a normal healing environment for a well-fixed fracture.

Key learning points

- A multidisciplinary approach is necessary to treat both acute injuries such as fractures and chronic causes such as nutritional vitamin D deficiency in a case of a non-traumatic bilateral femoral neck fracture.
- Adequate pre-operative optimization of the metabolic cause help to provide appropriate management.
- Regular follow with the team is necessary to prevent future consequences.

Informed consent

Patient parents have been informed about the publication of the case details and informed consent has been obtained from them.

Financial support and partnership

Financial support or grants of any kind were not required at any point of the publication.

Institutional ethical committee approval

Not required.

Author contributions

(I) Conception and design: Nishant D Goyal, Nikhil Valsangkar,

Shekhar Shrivastav, and Madhan Jeyaraman; (II) Administrative support: Madhan Jeyaraman (III); Provision of study materials or patients: Nishant D Goyal and Shekhar Shrivastav (IV); Collection and assembly of data: Nikhil Valsangkar and Madhan Jeyaraman; (V) Data analysis and interpretation: All authors; and (VI) Manuscript writing: All authors. All authors have read and agreed to the published version of the manuscript.

Declaration of competing interest

The authors have no conflict of interests to disclose.

References

1. Upadhyay A, Maini L, Batra S, Mishra P, Jain P. Simultaneous bilateral fractures of femoral neck in children–mechanism of injury. *Injury*. 2004;35(10):1073–1075. https://doi.org/10.1016/S0020-1383(03)00190-6.
2. Dhar D. Bilateral traumatic fracture of neck of femur in a child: a case report. *Malays Orthop J*. 2013;7(2):34–36. https://doi.org/10.5704/MOJ.1307.001.
3. Powell HDW. Simultaneous bilateral fractures of the neck of the femur. *J Bone Joint Surg Br*. 1960;42-B(2):236–252. https://doi.org/10.1302/0301-620X.42B2.236.
4. Cagırmaz T, Yapici C, Orak MM, Guler O. Bilateral femoral neck fractures after an epileptic attack: a case report. *Int J Surg Case Rep*. 2015;6:107–110. https://doi.org/10.1016/j.ijscr.2014.12.003.
5. M Shah H, Grover A, Gadi D, Sudarshan K. Bilateral neck femur fracture following a generalized seizure- A rare case report. *Arch Bone Jt Surg*. 2014;2(4):255–257.
6. Schnadower D, Agarwal C, Oberfield SE, Fennoy I, Pusic M. Hypocalcemic seizures and secondary bilateral femoral fractures in an adolescent with primary vitamin D deficiency. *Pediatrics*. 2006;118(5):2226–2230. https://doi.org/10.1542/peds.2006-1170.
7. Chandankere V, Mulpur P, Maryada VR, Pendyala SR, Annapareddy GV. Simultaneous bilateral neck of femur fractures in an adolescent secondary to hypocalcaemic seizure. *J Pediatr Orthop Part B*. 2019;28(5):491–494. https://doi.org/10.1097/BPB.0000000000000560.
8. Selek O, Memisoglu K, Selek A. Bilateral femoral neck fatigue fracture due to osteomalacia secondary to Celiac disease: report of three cases. *Arch Iran Med*. 2015;18(8):542–544, 015188/AIM.0012.
9. Narchi H, El Jamil M, Kulaylat N. Symptomatic rickets in adolescence. *Arch Dis Child*. 2001;84(6):501–503. https://doi.org/10.1136/adc.84.6.501.
10. Ladhani S, Srinivasan L, Buchanan C, Allgrove J. Presentation of vitamin D deficiency. *Arch Dis Child*. 2004;89(8):781–784. https://doi.org/10.1136/adc.2003.031385.
11. Vestergaard P. Epilepsy, osteoporosis and fracture risk - a meta-analysis. *Acta Neurol Scand*. 2005;112(5):277–286. https://doi.org/10.1111/j.1600-0404.2005.00474.x.
12. Kelly JP. Fractures complicating electro-convulsive therapy and chronic epilepsy. *J Bone Joint Surg Br*. 1954;36-B(1):70–79. https://doi.org/10.1302/0301-620X.36B1.70.
13. Vanderhooft E, Swiontkowski M. Bilateral femoral neck fractures following a grand mal seizure. *Ann Emerg Med*. 1994;24(6):1188–1191. https://doi.org/10.1016/s0196-0644(94)70254-3.
14. Guise TA, Mundy GR. Clinical review 69: evaluation of hypocalcemia in children and adults. *J Clin Endocrinol Metab*. 1995;80(5):1473–1478. https://doi.org/10.1210/jcem.80.5.7744987.