Dorsal Intradural Extramedullary Spinal Schwannoma

Clinical Image Description

A 30-year-old female presented with a history of inability to walk for the past week. On examination, there was appreciable hypertonia and cogwheel rigidity over bilateral lower limbs, with bladder incontinence. Reflexes were exaggerated with loss of sensations below the level of the D4 vertebra. Magnetic resonance imaging (MRI) of the dorsolumbar spine revealed an intramedullary lesion showing a split-fat sign in the sagittal section and a target sign in the coronal section, as shown in Figures 1a and b, respectively. The patient underwent in-toto removal of the tumour lesion, as shown in Figure 2. Histopathology of the tumorous lesion revealed hypercellular Antoni-A areas composed of compact, elongated cells with occasional nuclear palisading in pattern and hypocellular Antoni-B areas, as shown in Figure 3 which confirms the lesion to be a schwannoma. In the postoperative period, the patient reported the return of sensations below D4 vertebrae in 2 days. At the end of the 1-year follow-up, the patient was able to walk with support. The patient has been under follow-up for 3 years without any complications. Extramedullary lesions such as schwannoma have a very good prognosis, provided timely presentation and evaluation is employed to prevent irrecoverable myelopathy due to the mass effect of the lesion to the spinal medulla.

Spinal schwannomas are benign, intradural, extramedullary spinal tumours that arise from spinal nerve root sheaths. They generally occur in the fifth decade of life, are more common in males, and usually involve the lumbar spine.[1] Based on their membranous structure, they can be classified into interracial (type I), subarachnoidal (type II), intra-and extradural (type III), and extradural growth (type IV).[2] They can usually be diagnosed based on their appearance on MRI of a well-delineated intradural and extramedullary lesion of iso-to low signal intensity on T1-weighted images, high-signal intensity on T2-weighted images, and rim enhancement on contrast-enhanced images.[3] It is important to distinguish them from their closest differential diagnosis of spinal meningioma. Cystic appearance and a dumbbell shape favor schwannoma, whereas low-signal intensity on T2 weight MRI and an obtuse angle from the dura mater favor a diagnosis of meningioma.[4] The treatment recommended for schwannomas is the complete resection of the tumour, with only lesions involving more than two spinal segments and eroding vertebral bodies necessitating additional spinal stabilization.[5]

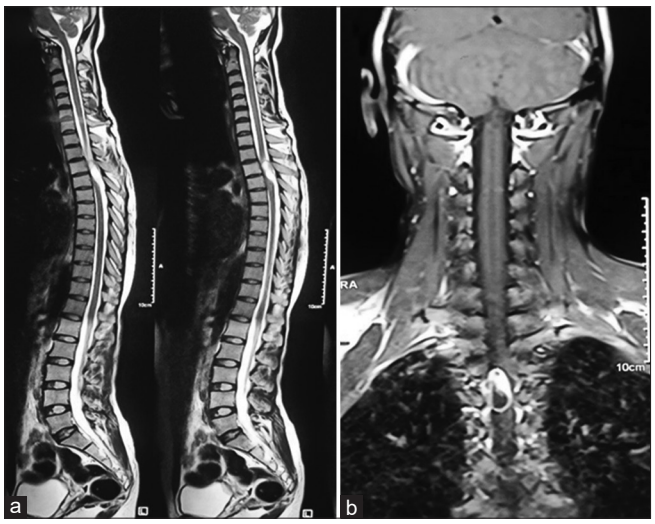

Figure 1: (a) MRI of dorsolumbar spine showing an intramedullary lesion, hypointense in T1 and heterogeneously hyperintense in T2 weighted image. A split-fat sign was noted in the sagittal section with a thin rim of fat on the long axis of the lesion; (b) MRI showing target sign in the coronal section with peripheral high T2 signal and central low signal intensity. MRI: Magnetic resonance imaging

Acknowledgment

I thank my professors Dr Rajni Ranjan and Dr Rakesh Kumar who helped me in operating this case.

Conflicts of interest

There are no conflicts of interest.

Informed consent

An informed consent was obtained from the patient for this publication.

Declaration of patient consent form

The authors certify that he has obtained all appropriate patient consent forms. In the form, the patient has given his consent for his images and other clinical information to be reported in

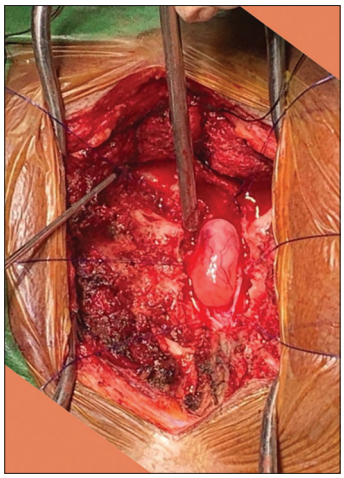

Figure 2: Intraoperative images showing a solid tumorigenic lesion at the level of D4 vertebra removed in-toto after open laminectomy

© 2022 Apollo Medicine | Published by Wolters Kluwer - Medknow

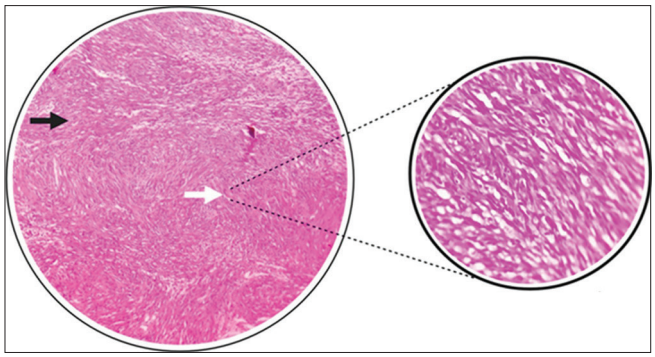

Figure 3: Histopathology examination of the tumorous lesion showing hypercellular Antoni A areas (light arrow) and hypocellular Antoni B areas (dark arrow) at ×40. The inset image shows the compact, elongated cells with an occasional nuclear palisading pattern of Antoni A areas at ×400

the journal. The patient understands that his name and initials will not be published, and due efforts will be made to conceal their identity, but anonymity cannot be guaranteed.

Funding

Nil.

Author contributions

All authors have contributed equally to writing the manuscript. All authors have read and agreed to the published version of the manuscript.

Madhan Jeyaraman[1], Naveen Jeyaraman[2], Arulkumar Nallakumarasamy[3]

[1]Department of Orthopaedics, Faculty of Medicine, Sri Lalithambigai Medical College and Hospital, Dr. MGR Educational and Research Institute, Chennai, [2]Department of Orthopaedics, Atlas Hospitals, Tiruchirappalli, Tamil Nadu, [3]Department of Orthopaedics, All India Institute of Medical Sciences, Bhubaneswar, Odisha, India

Address for correspondence: Dr. Madhan Jeyaraman, Department of Orthopaedics, Faculty of Medicine, Sri Lalithambigai Medical College and Hospital, Dr. MGR Educational and Research Institute, Chennai, Tamil Nadu, India.
E-mail: madhanjeyaraman@gmail.com

References

1. Jeon JH, Hwang HS, Jeong JH, Park SH, Moon JG, Kim CH. Spinal schwannoma; analysis of 40 cases. J Korean Neurosurg Soc 2008;43:135-8.
2. Xin Z, Orazmyradov B, Li J, Zhou Q, Peng L, Li H, *et al.* A novel classification and its clinical significance in spinal schwannoma based on the membranous hierarchy. Neurosurgery 2020;87:1206-22.
3. Netra R, Hui MS, Gang MZ, Ming Z. Spinal cystic schwannoma: An MRI evaluation. J Coll Physicians Surg Pak 2014;24:145-7.
4. Iwata E, Shigematsu H, Yamamoto Y, Kawasaki S, Tanaka M, Okuda A, *et al.* Preliminary algorithm for differential diagnosis between spinal meningioma and schwannoma using plain magnetic resonance imaging. J Orthop Sci 2018;23:408-13.
5. Paulo D, Semonche A, Tyagi R. Surgical management of lumbosacral giant invasive spinal schwannoma: A case report and literature review. World Neurosurg 2018;114:13-21.

This is an open access journal, and articles are distributed under the terms of the Creative Commons Attribution-NonCommercial-ShareAlike 4.0 License, which allows others to remix, tweak, and build upon the work non-commercially, as long as appropriate credit is given and the new creations are licensed under the identical terms.

Access this article online

Quick Response Code:

Website: www.apollomedicine.org

DOI: 10.4103/am.am_95_22

Submitted: 26-Jun-2022 **Revised:** 30-Aug-2022
Accepted: 01-Sep-2022 **Published:** 21-Sep-2022

How to cite this article: Jeyaraman M, Jeyaraman N, Nallakumarasamy A. Dorsal intradural extramedullary spinal schwannoma. Apollo Med 2022;19:S37-8.