World Journal of Clinical Cases

Submit a Manuscript: https://www.f6publishing.com

World J Clin Cases 2026 June 6; 14(16): 120594

DOI: 10.12998/wjcc.v14.i16.120594

ISSN 2307-8960 (online)

CASE REPORT

Os subepicondylare mediale ossicle as a cause for cubital tunnel syndrome: A case report

Arulkumar Nallakumarasamy, Sanjey Sivakumar, Vinnisa Nithiakala Vetrivel, Vinoth Prabhu Balaji, Norton Stephen, Naveen Jeyaraman, Madhan Jeyaraman

Peer review: Externally peer reviewed.
Peer-review model: Single blind
Peer-review report's classification
Scientific quality: Grade B, Grade B, Grade D
Novelty: Grade B, Grade B, Grade D
Creativity or innovation: Grade B, Grade B, Grade D
Scientific significance: Grade B, Grade B, Grade D
P-Reviewer: Nagamine T, MD, PhD, Professor, Japan; Su G, MD, PhD, China; Zheng L, PhD, Professor, China
Received: March 3, 2026
Revised: April 2, 2026
Accepted: April 30, 2026
Published online: June 6, 2026
Processing time: 80 Days and 14 Hours
Copyright: ©Author(s) 2026. This article is an open access article distributed under the terms and conditions of the Creative Commons Attribution-NonCommercial (CC BY-NC 4.0) license. No commercial re-use. See permissions. **Published by** Baishideng Publishing Group Inc.

Arulkumar Nallakumarasamy, Sanjey Sivakumar, Department of Orthopaedics, Jawaharlal Institute of Postgraduate Medical Education and Research, Karaikal 609602, Puducherry, India

Vinnisa Nithiakala Vetrivel, Department of Obstetrics & Gynecology, Vinayaka Mission Medical College and Hospital, Karaikal 609609, Puducherry, India

Vinoth Prabhu Balaji, Department of Orthopaedics, Government General Hospital, Karaikal 609602, Puducherry, India

Norton Stephen, Department of Pathology, Jawaharlal Institute of Postgraduate Medical Education and Research, Karaikal 609602, Puducherry, India

Naveen Jeyaraman, Madhan Jeyaraman, Department of Orthopaedics, ACS Medical College and Hospital, Dr MGR Educational and Research Institute, Chennai 600077, Tamil Nadu, India

Naveen Jeyaraman, Madhan Jeyaraman, Department of Regenerative Medicine, Agathisha Institute of Stemcell and Regenerative Medicine, Chennai 600030, Tamil Nadu, India

ORCID number: Arulkumar Nallakumarasamy 0000-0002-2445-2883; Sanjey Sivakumar 0009-0005-2932-3406; Norton Stephen 0000-0002-7410-3075; Naveen Jeyaraman 0000-0002-4362-3326; Madhan Jeyaraman 0000-0002-9045-9493.

Co-first authors: Arulkumar Nallakumarasamy and Sanjey Sivakumar.

Corresponding author: Madhan Jeyaraman, MD, PhD, Researcher, Department of Orthopaedics, ACS Medical College and Hospital, Dr MGR Educational and Research Institute, Velappanchavadi, Chennai 600077, Tamil Nadu, India. madhanjeyaraman@gmail.com

Abstract

BACKGROUND

Cubital tunnel syndrome is the second most common peripheral nerve entrapment syndrome after carpal tunnel syndrome. It involves compression of the ulnar nerve at the elbow, leading to pain, numbness, and weakness.

CASE SUMMARY

A 42-year-old male patient reported left elbow pain, tingling in the ring and small fingers, and a weak grip for 2 years. An X-ray revealed os subepicondylare mediale, a rare accessory ossicle that compressed the ulnar nerve. Decompression surgery and ossicle excision greatly improved symptoms and recovery.

CONCLUSION
Accessory ossicles are an important consideration in the differential diagnosis of ulnar neuropathy, and surgery has been shown to be an effective treatment in such cases.

Key Words: Cubital tunnel; Os subepicondylare; Medial ossicle; Ulnar nerve; Nerve entrapment; Case report

Core Tip: A 42-year-old male patient with cubital tunnel syndrome caused by an unusual accessory ossicle, os subepicondylare mediale, presented with elbow pain, finger tingling, and a weak grip. Imaging confirmed ulnar nerve compression. Surgical decompression with ossicle removal led to improvement in symptoms and function, highlighting the importance of considering accessory ossicles in ulnar neuropathy and the effectiveness of surgical treatment.

Citation: Nallakumarasamy A, Sivakumar S, Vetrivel VN, Balaji VP, Stephen N, Jeyaraman N, Jeyaraman M. Os subepicondylare mediale ossicle as a cause for cubital tunnel syndrome: A case report. *World J Clin Cases* 2026; 14(16): 120594
URL: https://www.wjgnet.com/2307-8960/full/v14/i16/120594.htm
DOI: https://dx.doi.org/10.12998/wjcc.v14.i16.120594

INTRODUCTION

Cubital tunnel syndrome (CuTS) is the second most common peripheral nerve entrapment syndrome after carpal tunnel syndrome. It involves compression of the ulnar nerve as it passes through the cubital tunnel at the elbow[1]. In addition to repetitive elbow flexion/extension and trauma, several uncommon causes of CuTS have been reported, including calcific neuritis[2], calcium pyrophosphate dihydrate disease[3], and heterotopic ossification secondary to burns or central nervous system injury[4]. Ulnar nerve compression may also arise from anatomical differences, such as the presence of accessory ossicles. In rare cases, ulnar neuropathy has been associated with os subepicondylare mediale, an accessory ossicle located near the medial epicondyle of the humerus. Although typically asymptomatic, its proximity to the ulnar nerve can lead to compression and neuropathy. This case report describes the diagnosis and successful treatment of ulnar neuropathy caused by os subepicondylare mediale and underscores the importance of considering such anatomical variants in patients presenting with unexplained ulnar nerve symptoms.

CASE PRESENTATION

Chief complaints

A 42-year-old man presented to the orthopedic outpatient department with a 2-year history of persistent medial elbow pain.

History of present illness

The patient reported intermittent pain, numbness and tingling in the ring and small fingers of his left hand, without any history of trauma or repetitive elbow flexion.

History of past illness

Nothing significant.

Personal and family history

Nothing significant.

Physical examination

Examination revealed moderate swelling over the medial aspect of the left elbow, along with weak hand grip, difficulty with fine motor tasks, and a Medical Research Council (MRC) grade of 2/5. Pain was exacerbated by movement and lifting heavy objects. Range of motion was within the normal range. There was weakness of the palmar interosseous and adductor pollicis muscles, with a positive Froment sign indicating weakness of the adductor pollicis. Two-point discrimination in the ulnar distribution (4th-5th digits) increased to 8 mm, consistent with sensory loss, and mild interosseous muscle wasting was noted. Symptoms were reproduced by percussion over the medial part of the left elbow, which spreads down along the ulnar distribution in the 4th and 5th digits.

Laboratory examinations

Electromyography and nerve conduction studies confirmed ulnar nerve compression at the cubital tunnel. Electrophysiological testing demonstrated a conduction delay across the elbow, consistent with mild ulnar neuropathy (Table 1).

Table 1 Electrophysiological parameters demonstrating conduction delay across the elbow consistent with mild ulnar neuropathy

Nerve	Latency (ms)	Amplitude mV (motor), μV (sensory)	Conduction velocity m/s	Interpretation
Left ulnar motor	4.8	5.2 mV	42	Conduction delay across the elbow
Left ulnar sensory	4.2	12 μV	38	Sensory conduction slowing
Median motor	3.4	8.5 mV	55	Normal
Radial sensory	2.8	18 μV	57	Normal

Normal reference values: Motor latency < 4.0 milliseconds, conduction velocity > 50 milliseconds; sensory latency < 3.5 milliseconds, amplitude > 10 μV (may vary by laboratory).

Imaging examinations

Radiographs demonstrated a well-defined oval-shaped osseous fragment under the medial epicondyle of the left elbow (Figure 1). Computed tomography (CT) confirmed a small, well-defined and corticated osseous structure located postero-medial to the medial epicondyle of the humerus, consistent with os subepicondylare mediale (Figure 2A). There was no evidence of fracture, cortical abnormality, dislocation, or joint pathology. Magnetic resonance imaging (MRI) revealed pathological ossification at the medial epicondylus, causing compression of the ulnar nerve within the cubital tunnel, with associated nerve edema and focal demyelination at the site of compression (Figure 2B). No soft tissue masses or other abnormalities were identified.

FINAL DIAGNOSIS

CuTS secondary to the os subepicondylare mediale ossicle.

TREATMENT

The ulnar nerve was surgically decompressed using a standard medial approach to the cubital tunnel. After incision of the skin and subcutaneous tissue, the ulnar nerve was identified and traced. The fascia between the two heads of the flexor carpi ulnaris was released, and the intermuscular plane was developed to achieve adequate decompression. An osseous spur was identified and removed to relieve compression of the nerve. Anterior transposition was not performed, as the nerve did not sublux intraoperatively after decompression (Figure 3).

Histopathological examination of the excised specimen demonstrated mature trabecular bone with interspersed marrow elements, consistent with an accessory ossicle (Figure 4).

OUTCOME AND FOLLOW-UP

Postoperatively, physiotherapy was initiated after the first wound inspection to improve range of motion and strengthen the musculature. A structured rehabilitation program, including early range-of-motion exercises followed by progressive strengthening, was implemented. No postoperative complications, such as infection, nerve instability, or recurrence were observed. The patient gradually transitioned to full activity over a period of 3 months.

At 1-year follow-up, the patient reported significant improvement in symptoms, with complete resolution of paresthesia in the 4th and 5th digits. Motor strength improved to MRC grade 5/5, and grip strength was comparable to the contralateral side. Two-point discrimination improved to 4 mm. Radiographic imaging confirmed successful removal of the accessory ossicle without evidence of recurrence (Figure 5).

DISCUSSION

Accessory ossicles of the elbow are an uncommon anatomical variant and may be mistaken for pathological conditions like avulsion fractures or calcifications. Although they are typically asymptomatic and incidentally identified on radiographic imaging, their location and proximity to the ulnar nerve can occasionally lead to symptomatic ulnar neuropathy[5,6].

Changes have been made to accessory ossicle classification since the original description by Wood and Campbell[6] and Kunc *et al*[7]. They introduced the term os subepicondylare mediale to describe type V accessory ossicles, refining the classification of anatomical variants around the elbow. They reported an overall prevalence of accessory ossicles of 0.77%,

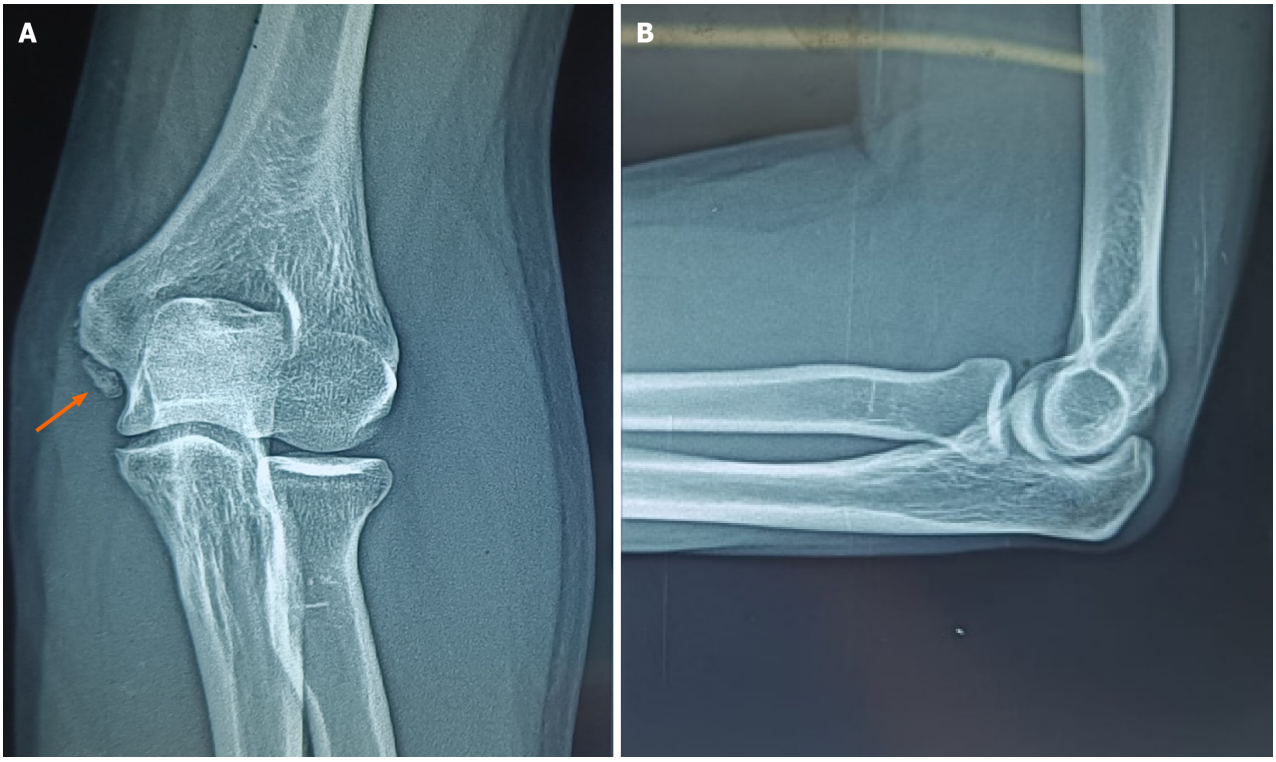

Figure 1 Plain radiograph of the left elbow. A and B: Anteroposterior and lateral view. The orange arrow indicates an accessory bone located beneath the medial epicondyle, featuring a distinctive, well-defined oval ossicle with smooth margins.

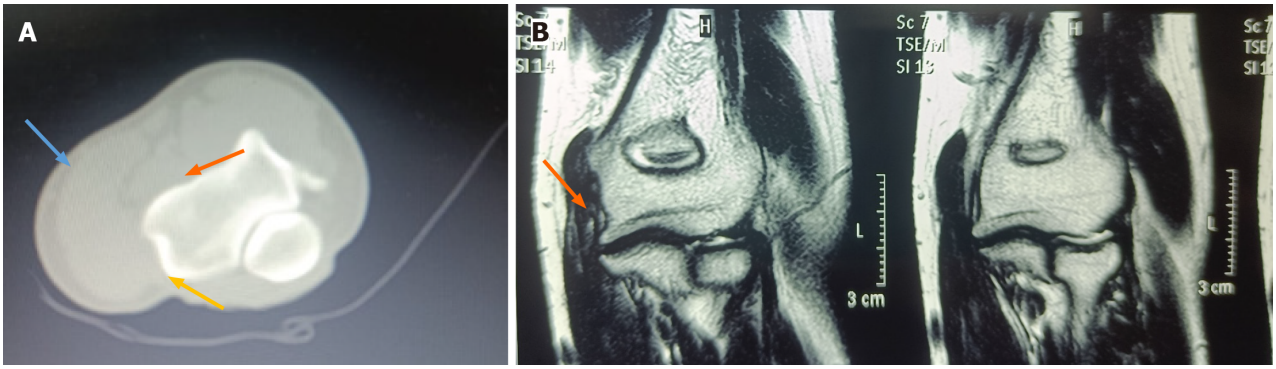

Figure 2 Computed tomography and magnetic resonance imaging. A: Computed tomography scan (sagittal view) of the left elbow joint (orange arrow = ossicle, blue arrow = medial humeral epicondyle, yellow arrow = ulna); B: Magnetic resonance imaging of the left elbow joint. The orange arrow indicates the small corticated ossicle separated from the medial epicondyle with a thin, low-intense signal cleft. It lies within or adjacent to the ulnar collateral ligament; the fibers remain continuous. The fragment demonstrates marrow signal identical to native bone with thickened ulnar nerve (T1 hyperintense, T2 intermediate), suggestive of synchondrosis (accessory ossicle).

with being os subepicondylare mediale being the most common (0.46%), located just below the medial epicondyle[7]. A case of ulnar nerve neurapraxia caused by accessory ossicles and instability was described by Poelstra *et al*[8], supporting the clinical significance of these anatomical variants. These findings underscore the importance of considering accessory ossicles in the differential diagnosis of ulnar neuropathy, even in the absence of trauma or instability, as in the present case. Kunc *et al*[7] emphasized the role of accessory ossicles in ulnar neuropathy related to pathologic ossification. They reported that excision of the ossicle combined with ulnar nerve release, often with anterior subcutaneous transposition, is an effective treatment approach[9]. Although anterior transposition is commonly recommended, in our case, simple decompression with ossicle removal was sufficient, as the ulnar nerve was stable during the operation.

In our case, CuTS was caused by an accessory ossicle adjacent to the medial epicondyle (os subepicondylare mediale). The patient presented with a typical clinical course, including pain, numbness, and tingling in the ring and small fingers (4th and 5th digits), along with hand grip weakness. Radiographic imaging was essential in distinguishing the accessory ossicle from other possible causes of nerve compression. Sesamoids and accessory ossicles are often misdiagnosed as avulsion fractures, osteochondritis dissecans, calcific tendinitis, or synovial chondromatosis[10]. In this case, the unique, clear bone structure supported the diagnosis a sesamoid bone rather than a loose body.

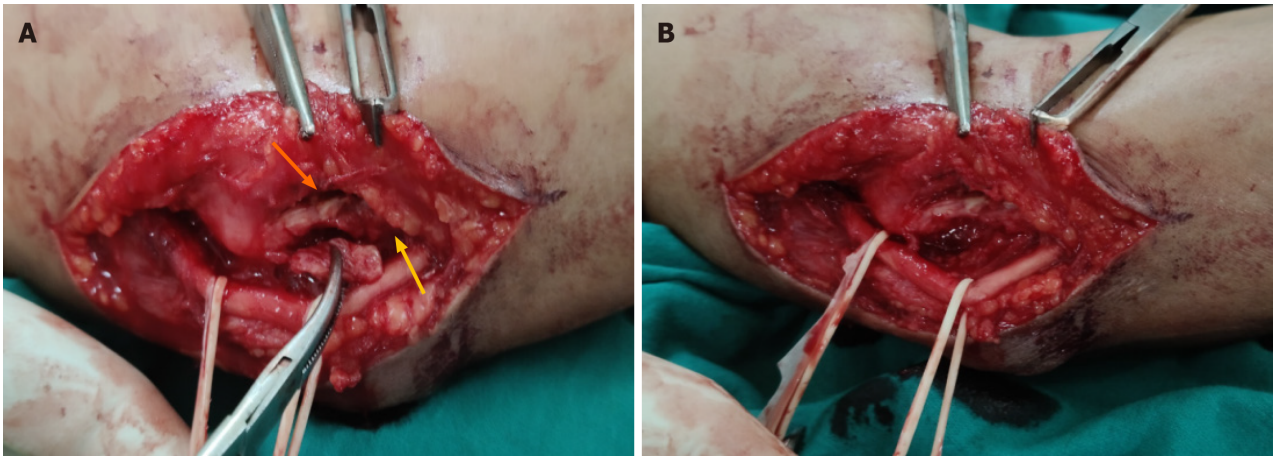

Figure 3 Intraoperative images. A: An ossicle was identified (orange arrow) and carefully excised through the Taylor and Scham approach to relieve compression on the ulnar nerve; B: The yellow arrow indicates the ulnar nerve, retracted and freed from the accessory ossicle.

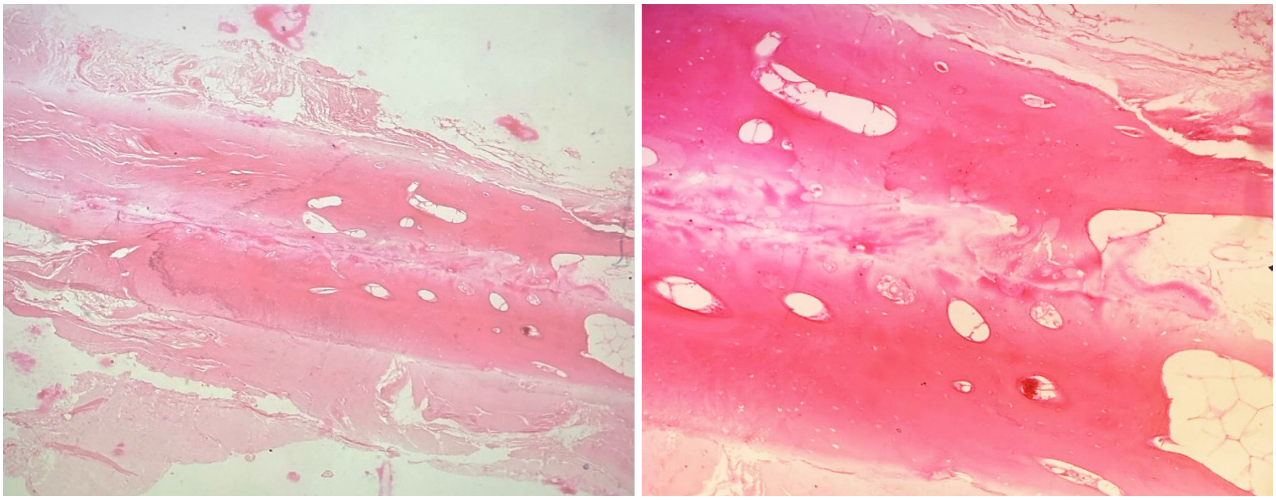

Figure 4 Histopathological examination of the excised specimen. Histopathological examination showing mature bony trabeculae with interspersed marrow fat (H&E stain; 10 × and 40 × magnification).



Figure 5 At 1-year follow-up, the hand grip strength had returned to near-normal levels with complete restoration of the range of movements with no radiological recurrence.

The patient required surgical intervention, consisting of excision of the accessory ossicle and decompression of the ulnar nerve, which resulted in symptom relief. This favorable outcome underscores the importance of considering accessory ossicles as a possible cause of CuTS, particularly in patients who do not respond to conservative treatment.

CONCLUSION

Although rare, os subepicondylare mediale should be considered in cases of unexplained CuTS. Multimodal imaging is essential for identifying such anatomical variants, and timely surgical decompression can yield excellent functional outcomes. This case highlights the role of multimodal imaging in identifying accessory ossicles and underscores the importance of clinical awareness and accurate radiographic evaluation in diagnosing accessory ossicles and guiding effective management.

REFERENCES

1 **Andrews K**, Rowland A, Pranjal A, Ebraheim N. Cubital tunnel syndrome: Anatomy, clinical presentation, and management. *J Orthop* 2018; **15**: 832-836 [*RCA*] [PMID: 30140129 DOI: 10.1016/j.jor.2018.08.010] [FullText]

2 **Ametewee K**. Acute cubital tunnel syndrome from post-traumatic calcific neuritis. *J Hand Surg Br* 1986; **11**: 123-124 [*RCA*] [PMID: 3958533 DOI: 10.1016/0266-7681(86)90033-1] [FullText]

3 **Aoyama T**, Takahashi S. Cubital tunnel syndrome caused by tumoral deposition of calcium pyrophosphate dihydrate crystals: a case report. *J Shoulder Elbow Surg* 2001; **10**: 194-196 [*RCA*] [PMID: 11307086 DOI: 10.1067/mse.2001.112057] [FullText]

4 **Özişler Z**, Yalçın E, Özel S. Ulnar neuropathy due to heterotopic ossification: A rare complication after stroke. *Turk J Phys Med Rehabil* 2018; **64**: 173-175 [*RCA*] [PMID: 31453509 DOI: 10.5606/tftrd.2018.62993] [FullText]

5 **Kunc V**, Salavova S, Kachlik D. Osseous variability around the elbow joint. *Acta Radiol* 2023; **64**: 1540-1545 [*RCA*] [PMID: 36221852 DOI: 10.1177/02841851221129392] [FullText]

6 **Wood VE**, Campbell GS. The supratrochleare dorsale accessory ossicle in the elbow. *J Shoulder Elbow Surg* 1994; **3**: 395-398 [*RCA*] [PMID: 22958845 DOI: 10.1016/S1058-2746(09)80026-8] [FullText]

7 **Kunc V**, Kunc V, Černý V, Polovinčák M, Kachlík D. Accessory bones of the elbow: Prevalence, localization and modified classification. *J Anat* 2020; **237**: 618-622 [*RCA*] [PMID: 32839981 DOI: 10.1111/joa.13233] [FullText]

8 **Poelstra KA**, Flint JH, Chhabra AB, Pannunzio ME. Ulnar nerve neurapraxia in the presence of instability and anomalous ossicles at the elbow: a case report. *J Shoulder Elbow Surg* 2006; **15**: e11-e14 [*RCA*] [PMID: 16963288 DOI: 10.1016/j.jse.2005.08.003] [FullText]

9 **Vojtěch K**, David K, Ivan H. Ulnar nerve neuropathy caused by pathologic ossification: a case report. *Surg Radiol Anat* 2023; **45**: 1107-1110 [*RCA*] [PMID: 37566256 DOI: 10.1007/s00276-023-03217-5] [FullText]

10 **Doğan Y**. Radiographic and Ultrasonographic Evaluation of the Rare Sesamoid Bone of the Elbow: Os Subepicondylare Mediale. *Curr Med Imaging* 2023 [*RCA*] [PMID: 37038669 DOI: 10.2174/1573405620666230405094331] [FullText]

FOOTNOTES

Specialty type: Orthopedics

Country of origin: India

Author contributions: Nallakumarasamy A and Jeyaraman N designed the research; Nallakumarasamy A, Sivakumar S, Vetrivel VN, Balaji VP, Stephen N, and Jeyaraman M analyzed articles for the review and wrote the manuscript; Jeyaraman M finalized the manuscript.

Informed consent statement: Written informed consent was obtained from the patient for publication of this report and any accompanying images.

Conflict-of-interest statement: The authors declare no conflict of interest in the manuscript.

CARE Checklist (2016) statement: The authors have read the CARE Checklist (2016), and the manuscript was prepared and revised according to the CARE Checklist (2016).

S-Editor: Liu JH

L-Editor: Filipodia

P-Editor: Xu J

Published by **Baishideng Publishing Group Inc**
7041 Koll Center Parkway, Suite 160, Pleasanton, CA 94566, USA
Telephone: +1-925-3991568
E-mail: office@baishideng.com
Help Desk: https://www.f6publishing.com/helpdesk
https://www.wjgnet.com

© 2026 Baishideng Publishing Group Inc. All rights reserved.